

Role of diagnostic laparoscopy in abdominal disorders with uncertain diagnosis: a rare case report

Mykola I. Kravtsiv, Maxym O. Dudchenko, Dmytro M. Ivashchenko, Mykola P. Shevchuk, Oleh H. Krasnov, Tamara V. Horodova-Andrieieva, Olexandr M. Liulka
POLTAVA STATE MEDICAL UNIVERSITY, POLTAVA, UKRAINE

ABSTRACT

Female patient was hospitalized in the surgical of the Municipal Enterprise "2nd City Clinical Hospital of Poltava City Council" (Poltava, Ukraine) in 2023. The patient underwent a complete general clinical examination, a plain radiograph of the abdominal cavity, fibrogastroduodenoscopy, colonoscopy, ultrasound of the abdominal organs, CT scan of the abdominal organs. Diagnostic laparoscopy was performed to make a final diagnosis.

A plain radiography of the abdominal cavity revealed no pathology. Ultrasound of the abdominal organs revealed a pelvic mass. A computed tomography scan revealed damage to the pelvic organs in the form of a neoplasm and an enlargement of the left ovary. The preliminary diagnosis was a pelvic tumor, tumor of the left ovary. Diagnostic laparoscopy was performed to make the diagnosis. A rounded formation was defined in Douglas space. The capsule of the formation was opened and pus was released. The abscess wall was opened, and a foreign body (gauze pad) was removed from the cavity. The patient was discharged from the hospital in satisfactory condition on the fifth day after surgery.

The case we examined emphasizes that when assessing the nature of an intra-abdominal neoplasm, it is necessary to remember about foreign bodies, especially in patients after surgical interventions. Diagnostic laparoscopy is a technically advanced and minimally invasive procedure for the diagnosis and treatment of intra-abdominal gossypiboma.

KEY WORDS: foreign body, diagnostic laparoscopy, gossypiboma, abdominal cavity

Wid Lek. 2025;78(2):479-486. doi: 10.36740/WLek/200416 DOI

INTRODUCTION

Cancer is a major public health problem worldwide and the second leading cause of death in the United States [1]. Cancer accounts for 21% of all deaths in both men and women and is the second leading cause of death after heart diseases. However, it is the leading cause of death among women aged 40 to 79 years and men aged 60 to 79 years [1].

The main criterion for adequate treatment of patients with abdominal tumors is timely identification of the problem and accuracy of clinical diagnosis. That is why a comprehensive examination of the patient at the pre-hospital and hospital stages plays an important role in achieving the final result of treatment [2, 3].

Modern standards for diagnosing abdominal tumors in patients include: ultrasound examination of the abdominal cavity as a screening diagnostic method, magnetic resonance imaging, multislice computed tomography with intravenous contrast [2, 3]. However, the gold standard for diagnosing almost all types of malignant neoplasms is positron emission computed

tomography (PET-CT) [4]. Its principle is to visualize the activity of the body at the cellular level, in contrast to Magnetic Resonance Imaging (MRI) and Multi-slice computed tomography (MSCT), which show only the structure of the organ [5, 6].

The main disadvantage of PET-CT in diagnosing tumors in Ukraine is the lack of sufficient necessary equipment to conduct such studies. Now in our country there are only four such tomographs [7]. At the same time, according to the European Association of Nuclear Medicine, for adequate diagnosis of the tumor process, one PET-CT device is needed to examine 1.5-2 million people [5].

In this regard, we proposed to use another method for the diagnosis and treatment of abdominal tumors, namely diagnostic laparoscopy, as an invasive method for diagnosing pathology of the abdominal and pelvic organs [8]. We use this diagnostic method in cases where other methods did not give an accurate result or their data differ significantly from each other. Diagnostic laparoscopy has a number of advantages: small wound

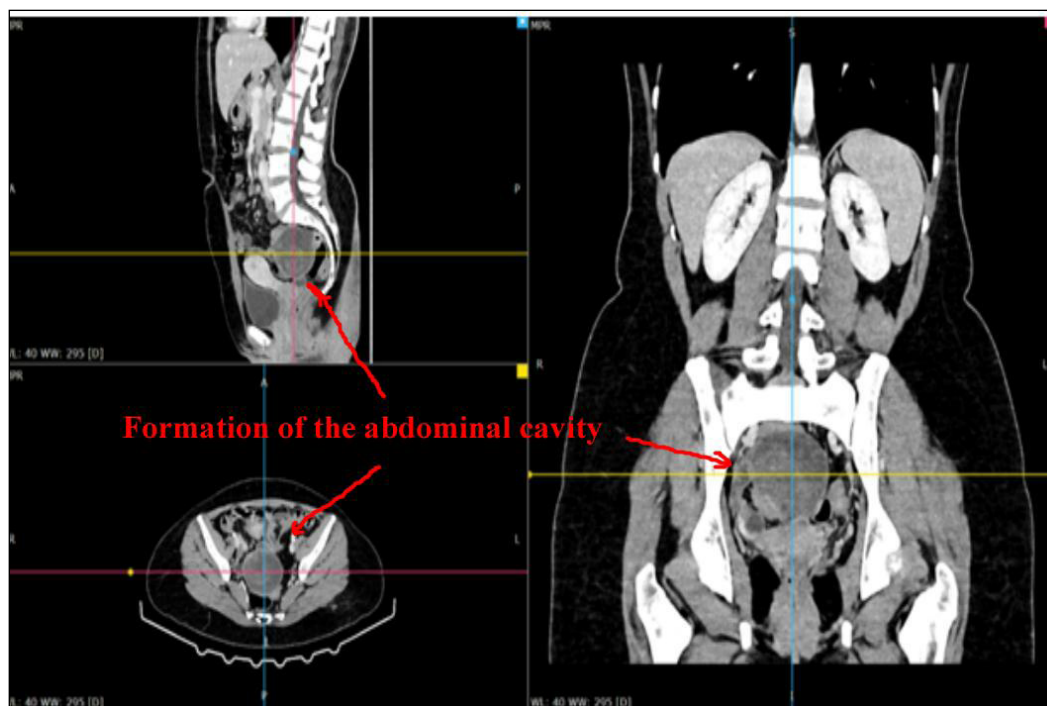


Fig. 1. MSCT of the abdomen and pelvis: axial section and frontal section.

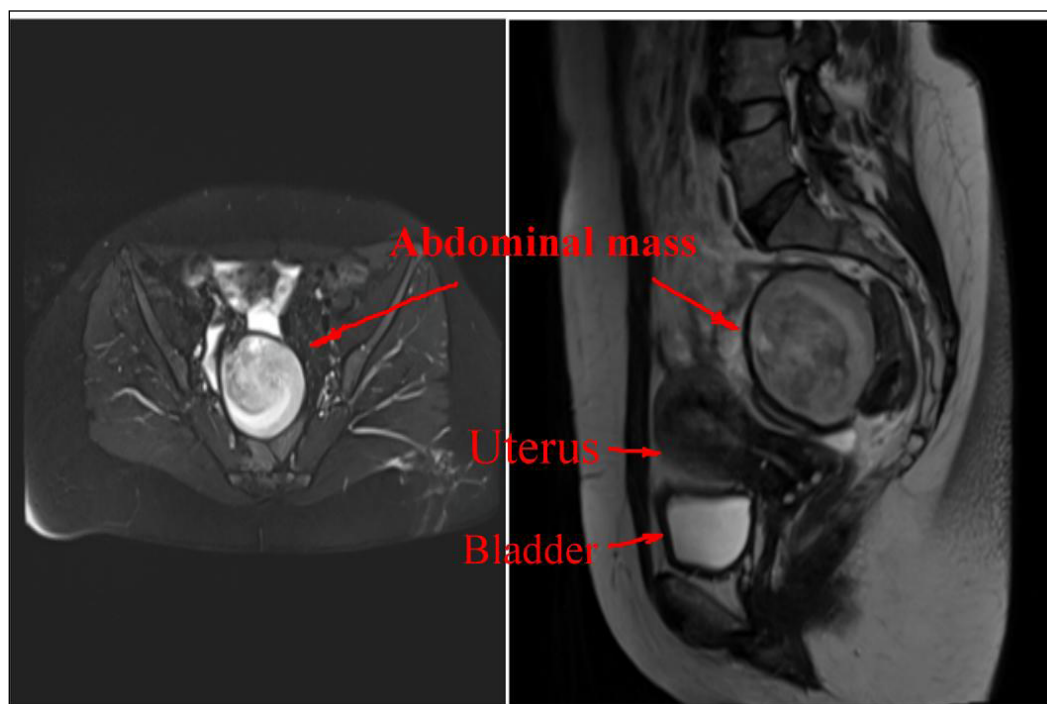


Fig. 2. MRI of the abdominal cavity. Abdominal mass.

sizes, rapid patient recovery, minimal risk of infection, absence of scars, and most importantly, the ability to perform a biopsy during the procedure [9, 10].

In some cases, abdominal tumors have to be differentiated from various foreign bodies, especially in those patients who have previously undergone surgical interventions [11, 12]. This differential diagnosis always causes great difficulties, even when using the entire range of non-invasive studies.

In the United States, more than 28 million surgical procedures are performed annually, and about 1.5

thousand cases of retained foreign bodies are detected among them. Foreign bodies in the abdominal cavity are a serious problem for surgeons and patients, with an average incidence of 0.3-1.0 cases per thousand abdominal surgeries [11]. Foreign bodies may appear immediately after surgery and require emergency surgery or remain undetected for months or years. All foreign bodies can cause various complications: pain, abscess, intestinal obstruction or perforation, gastrointestinal fistula, etc. [12].

Such foreign bodies in the abdominal cavity include gossypiboma [12, 13]. The term gossypiboma

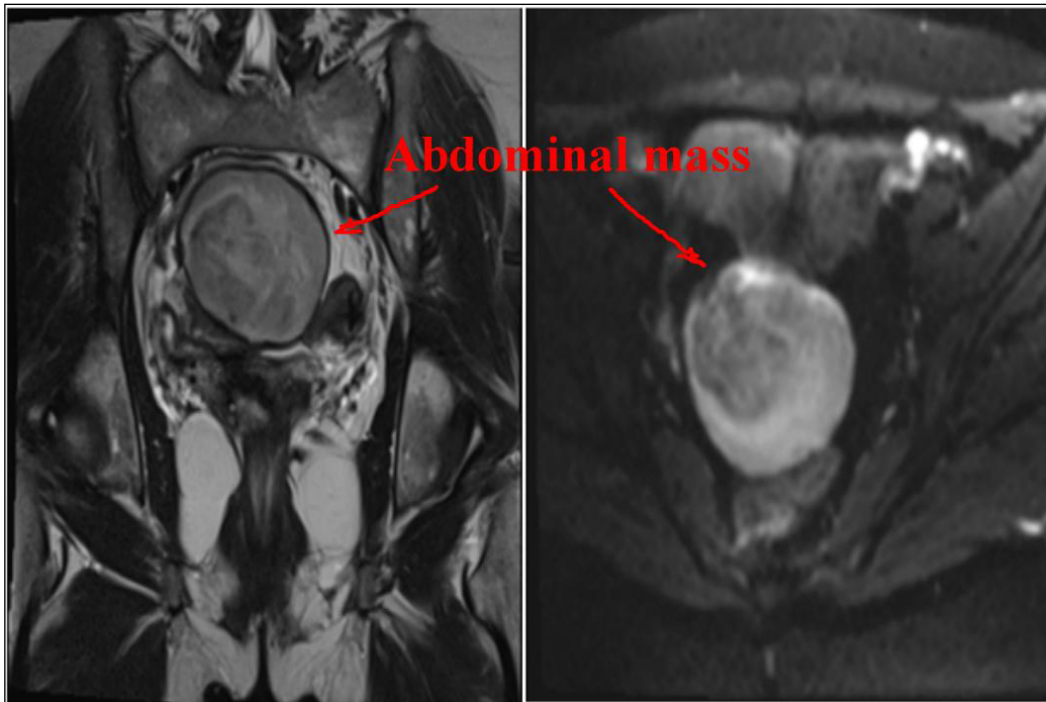


Fig. 3. MRI of the abdominal cavity. Abdominal mass.

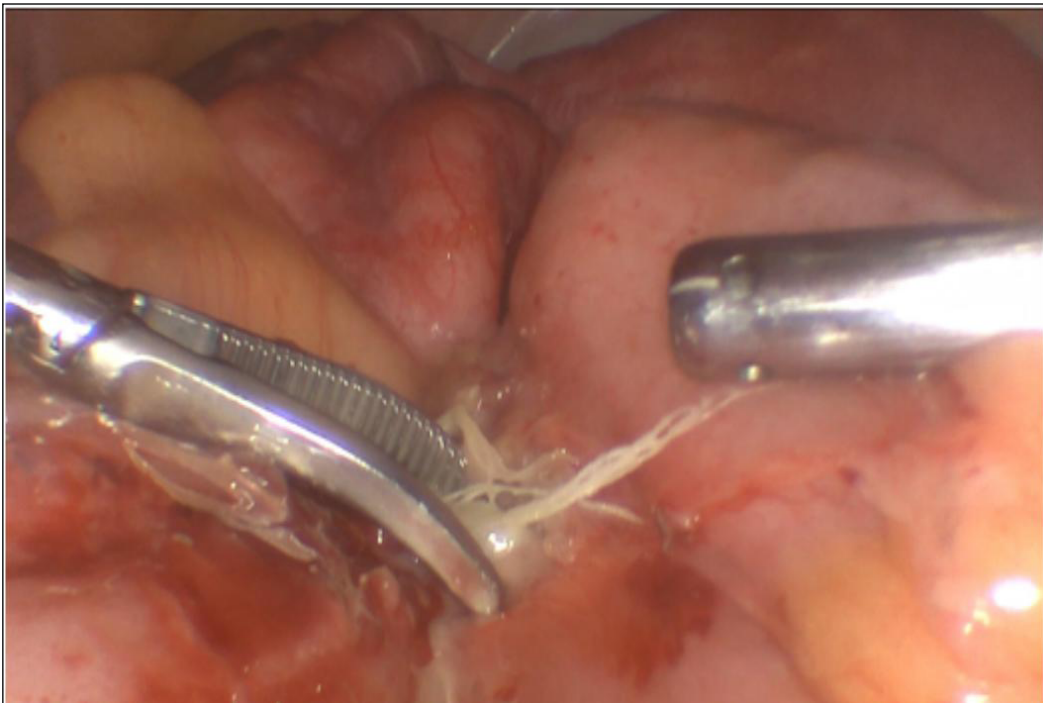


Fig. 4. Per operative images of the changes found in patient M., 39 years old.

was first described by Wilson in 1884 to refer to the unknowing abandonment of a surgical gauge or sponge in a body cavity following a surgical procedure [14, 15]. It is an infrequent but serious surgical complication that is rarely reported due to its medico-legal implications. This usually causes an exudative inflammatory reaction with the formation of an abscess or aseptic fibrosis with the formation of a mass that leads to future complications such as intestinal obstruction [15]. It can appear within a few

days, and sometimes even several years after surgery. Gossypiboma is a serious surgical complication that impacts patient safety, cost of care, and can lead to mortality if diagnosis and treatment are delayed. Its clinical manifestations are extremely varied, so diagnosis is quite difficult [16, 17].

Thus, the search and implementation of new informative and reliable non-invasive and minimally invasive methods for diagnosing neoplasms and foreign bodies of the abdominal cavity is now very relevant.

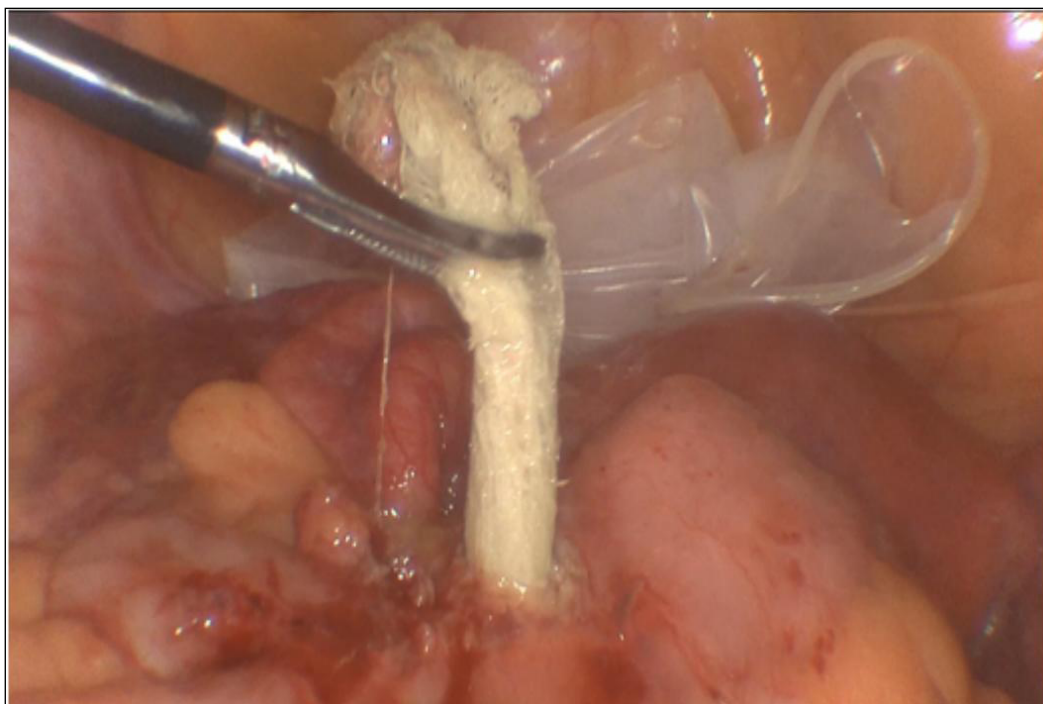


Fig. 5. Per operative images of the changes found in patient M., 39 years old: detected foreign body (gauze wad).

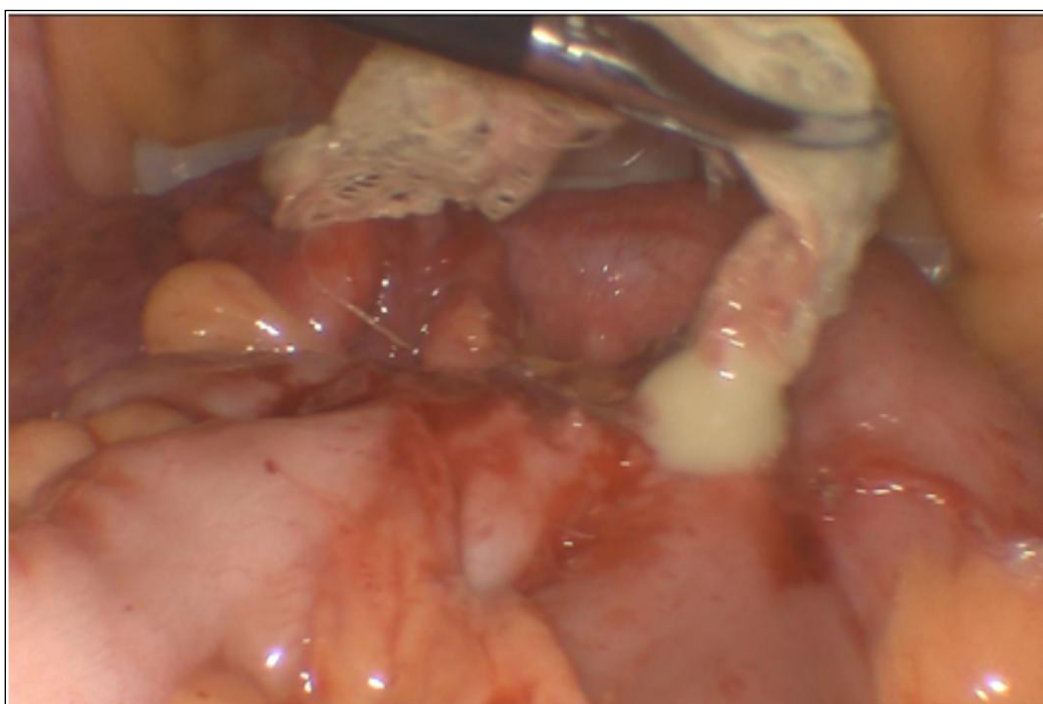


Fig. 6. Per operative images of the changes found in patient M., 39 years old: foreign body with discharge of pus from the abscess cavity.

CASE REPORT

Female patient M., born in 1985, was routinely hospitalized in the surgical of the Municipal Enterprise "2nd City Clinical Hospital of Poltava City Council" (Poltava, Ukraine) in 2023. The patient underwent a complete general clinical examination, determination of tumor markers, serological tests for amebiasis and echinococcus, a plain radiograph of the abdominal cavity, fibrogastroduodenoscopy, colonoscopy, ultrasound of the abdominal organs, CT scan of the abdominal organs. Diagnostic laparoscopy was performed to make a final diagnosis.

The patient complained of constant aching pain in the lower abdomen, predominantly on the left, radiating to the lumbar region, nausea without bloating, fatigue, and weakness for three months. The passage of feces and gases was preserved.

As it became known from the anamnesis, the patient was operated on twice in gynecological departments: in 2019 there was a laparotomy for a cyst of the left ovary with a Pfannenstiel incision, and in 2021 a laparoscopic cystectomy was performed on the left.

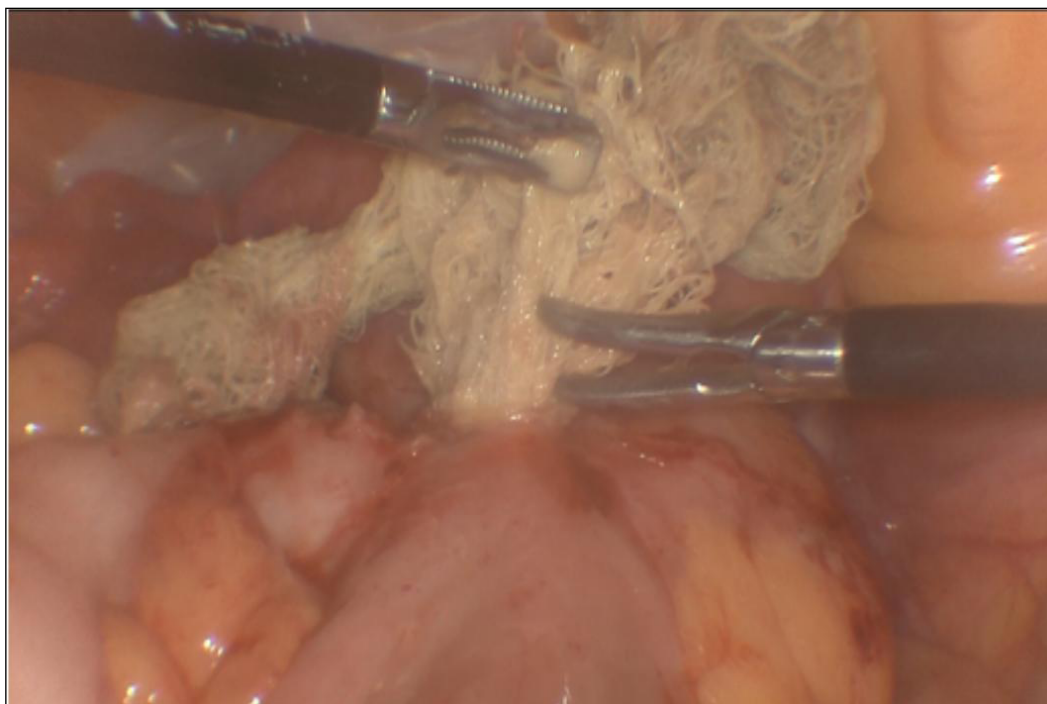


Fig. 7. Per operative images of the changes found in patient M., 39 years old: blunt removal of a foreign body (gauze wad).

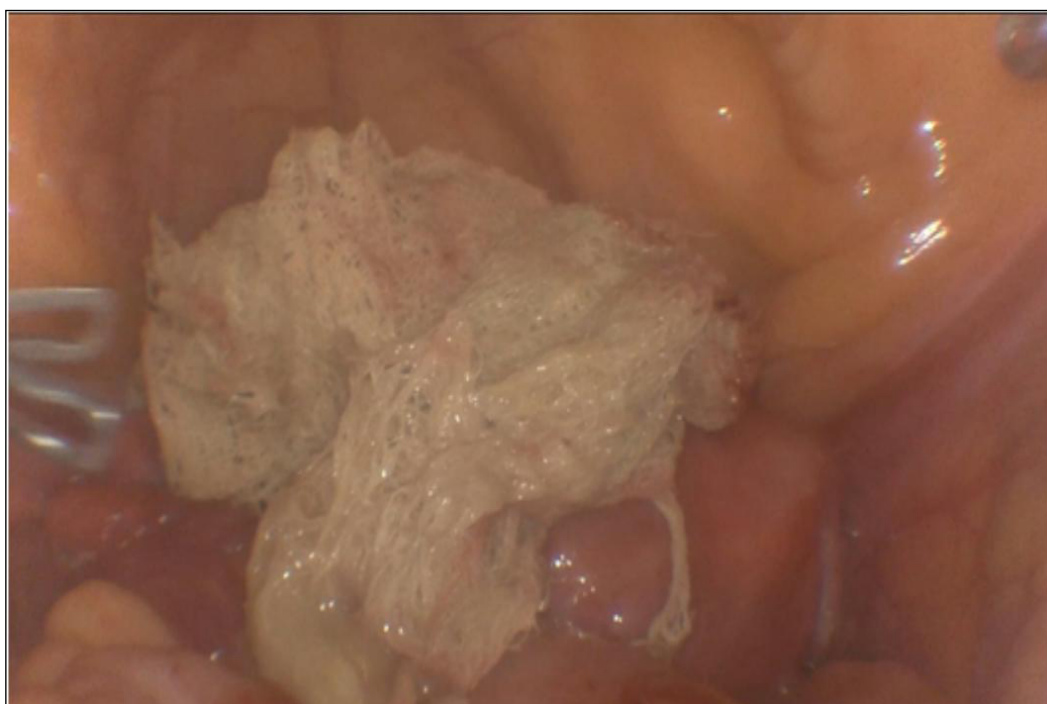

Fig. 8. Per operative images of the changes found in patient M., 39 years old: foreign body (gauze wad) removal.

An objective examination revealed: blood pressure 120/70 mm. Hg, pulse 98 beats per minute, respiratory rate 18 per minute, body temperature 36.8 C. Examination of the abdominal cavity revealed a painful mass in the left lower quadrant and slight tenderness in the periumbilical region. During a laboratory examination, the patient's hemoglobin level was within normal limits, the leukocyte count was $9.2 \times 10^9/l$ (80% neutrophils), hematocrit – 39%, platelet count – $345 \times 10^9/l$. A plain radiography of the abdominal cavity revealed no pathology.

Fibergastroduodenoscopy did not reveal any organic pathology. Colonoscopy revealed erythematous proctitis. When performing an endometrial biopsy, the endometrium is in a disturbed phase of proliferation. When examining tumor markers: CA 125 – 88.4 U/ml, HE 4 – 44.2 pmol/l, ROMA index – 6.28%. Serological tests for amoebiasis and echinococcus were negative. Ultrasound of the abdominal organs showed a pelvic mass of a heterogeneous structure measuring 7.5 by 7.6 cm, small uterine leiomyoma, type 4.

A computed tomography scan revealed a complex localized lesion of the pelvic organs in the form of a

hypodense formation measuring 8.2 by 8 by 7.5 cm with peripheral enhancement and hemorrhagic contents, and an enlargement of the left ovary (Fig.1).

An MRI of the abdominal cavity and pelvis revealed a tumor of the left ovary and adenomyosis of the uterus I-II (Fig.2, Fig.3).

A preliminary diagnosis was made: Mass formation of the pelvis. Tumor of the left ovary. Small uterine leiomyoma.

Due to discrepancies in the results of non-invasive research methods, the patient was offered diagnostic laparoscopy to make a final diagnosis. The patient was warned about possible options for completing the surgical intervention (conversion, bowel resection, surgical sterilization, hysterectomy, etc.). Consent for the operation was obtained.

Elective diagnostic laparoscopy was performed. During the revision operation, it was revealed that the stomach, gallbladder, and liver were without organic pathology. The patient was transferred to the Trendelenburg position. When examining the pelvic organs, the uterus and right appendages were unchanged. The left ovary was enlarged (up to 5 cm) due to a cystic formation, the ovarian tissue was located on the periphery. The left fallopian tube was unchanged. A rounded formation measuring up to 15 cm in diameter was detected in Douglas space. It was densely elastic consistency, limited movable. The loops of the small intestine and the sigmoid colon were tightly fused to it. Viscerolysis was performed using a blunt method and using electrocoagulation, during which the integrity of the capsule of the formation was disrupted, and up to 150 ml of thick, cream-like pus was released (Fig. 4). This situation was previously assessed as a pelvic abscess. The abscess wall was opened up to 2 cm, with a section of foreign body (gauze wad) protruding from the cavity (Fig. 5, Fig. 6, Fig. 7, Fig. 8).

The foreign body was removed from the abdominal cavity in a container. The abscess cavity was opened and drained. After a bacteriological examination of the abscess contents, no bacterial cultures were found.

The course of the postoperative period was uncomplicated. The drains were removed from the abdominal cavity on the fifth day of the postoperative period. The patient was discharged from the hospital in satisfactory condition on the fifth day after surgery.

During follow-up examinations one, three, and six months after surgery, the patient did not present any complaints. When conducting a control ultrasound of the abdominal cavity after three and six months, no pathological formations were detected in the abdominal cavity and pelvis.

Abdominal foreign bodies may not manifest themselves clinically for several months or years, but may be

diagnosed by chance [14]. The biggest problem is that this foreign body is often interpreted as a malignancy, which leads to additional problems in the diagnosis and treatment of such patients [12, 14]. Having no specific symptoms, clinical manifestations vary from an asymptomatic course to constant abdominal pain, nausea, vomiting, intestinal obstruction, fistulas, sepsis, and in some cases, diffuse peritonitis [14,16].

According to statistics, the greatest number of cases with foreign bodies left behind occurs precisely in emergency surgery (about 85-90%), which is associated with the increased amount of stress, fatigue of the surgeon, since the operation can be performed at night, or when unplanned events take place during the procedure, etc [12, 13, 17].

A surgical gauze is the most frequent item that can be left in the abdominal cavity, in contrast to surgical instruments, gloves, which occurs more rarely. Gossypiboma, this term comes from Latin "gossypium" (cotton) and Swahili "boma" (shelter), that means surgical dressing material (gauze wads, tampons, etc.) forgotten in cavities. Women are especially exposed to high risk (63%) since gossypiboma often occurs after gynecological surgery [14, 15, 16].

MSCT with intravenous contrast is the gold standard for the diagnosis of foreign bodies in the abdominal cavity all over the world [2, 3, 7]. In the mentioned above clinical case, none of the additional, non-invasive, diagnostic methods had shown a result "in the direction" of a foreign body, and performing a diagnostic laparoscopy enables to make a clinical diagnosis and carry out surgical treatment without performing a more traumatic "open" surgery [8, 9, 10].

In order to exclude errors and prevent from leaving foreign bodies, close cooperation between the surgeon and the operating nurse is necessary: while the counting of gauze wads, distractions, interruptions or breaks are not allowed, and the counting method must be consistent; the operation is not finished until all gauze wads or instruments have been counted [18, 19, 20].

In order to prevent similar situation, we recommend the use of gauze wads with radiopaque markers, in this case, radiography on the operating table, can help even before the end of the operation. If there are any doubts, repeated revision of the operative field is needed.

CONCLUSIONS

The case we examined emphasizes that when assessing the nature of an intra-abdominal neoplasm, it is necessary to remember about foreign bodies, especially in patients who have previously undergone surgical interventions. Diagnostic laparoscopy is a technically advanced and minimally invasive procedure for the diagnosis and treatment of intra-abdominal gossypiboma.

REFERENCES

- Howlader N, Noone AM, Krapcho M et al. SEER Cancer Statistics Review, 1975–2018. National Cancer Institute. 2021. https://seer.cancer.gov/csr/1975_2018/ [Accessed 25 June 2024]
- Adama S, Balaraba M, Aliou Z et al. Diagnostic and therapeutic approach to abdominal masses in a country with limited resources. *BMC Surg.* 2024;24(1):97. doi: 10.1186/s12893-024-02371-w. [DOI](#)
- Akkoca M, Tokgoz S, Yilmaz BK et al. Diagnosis and treatment approaches for intraabdominal masses in adults. *Ankara Universities Tip Fakultesi Mesmuasi, Turkiye* 2017;70(3). doi: 10.1501/Tipfak_0000000987. [DOI](#)
- Joo Hyun O, Lodge MA, Wahl RL. Practical PERCIST: a simplified guide to PET response criteria in solid tumors 1.0. *Radiology.* 2016;280:576–584. doi:10.1148/RADIOL.2016142043. [DOI](#)
- Pinker K, Riedl C, Weber WA. Evaluating tumor response with FDG PET: updates on PERCIST, comparison with EORTC criteria and clues to future developments. *Eur J Nucl Med Mol Imaging.* 2017;44:55–66. doi:10.1007/S00259-017-3687-3. [DOI](#)
- Altini C, Lavelli V, Ruta R et al. Typical and atypical PET/CT findings in non-cancerous conditions. *Hell J Nucl Med.* 2020;23(1):48–59. doi: 10.1967/s002449912005. [DOI](#)
- Dzhuzha DA. Radiation visualization in radiation oncology. *Radiation Diagnostics, Radiation Therapy.* 2020;3:39–48. doi:10.37336/2707-0700-2020-3-4. [DOI](#)
- Leimkühler M, de Haas RJ, Pol VE et al. Adding diagnostic laparoscopy to computed tomography for the evaluation of peritoneal metastases in patients with colorectal cancer: A retrospective cohort study. *Surg Oncol.* 2020;33:135–140. doi: 10.1016/j.suronc.2020.02.010. [DOI](#)
- El Zanati HI, Aboelwafaa WA, Hamza YM. The role of diagnostic laparoscopy in abdominal masses. *Int Surg J.* 2020;7(4):945–9. doi:10.18203/2349-2902.isj20201370. [DOI](#)
- Yeola ME, Gode D, Bora A. Diagnostic Laparoscopy as an Effective Tool in Evaluation of Intra-abdominal Malignancies. *World Journal of Laparoscopic Surgery.* 2018;11. 68–75. doi:10.5005/jp-journals-10033-1338. [DOI](#)
- Hempel S, Maggard-Gibbons M, Nguyen DK et al. Wrong-site surgery, retained surgical, items, and surgical fires a systematic review of surgical never events. *JAMA Surg.* 2015;150(8):796–805. doi: 10.1001/jamasurg.2015.0301. [DOI](#)
- Zejnnullahu VA, Bicaj BX, Zejnnullahu VA, Hamza AR. Retained surgical foreign bodies after surgery. *Open Access Maced J Med Sci.* 2017;5(1):97–100. doi: 10.3889/oamjms.2017.005. [DOI](#)
- Sonarkar R, Wilkinson R, Nazar Z et al. Textiloma presenting as a lump in abdomen: a case report. *Int J Surg Case Rep.* 2020;77:206–9. doi: 10.1016/j.ijscr.2020.10.081. [DOI](#)
- Bairwa BL. Gossypiboma – an unusual cause of surgical abdomen and surgeon’s nightmare: A rare case report. *Int J Surg Case Rep.* 2021;80:105521. doi: 10.1016/j.ijscr.2021.01.015. [DOI](#)
- Ram T, Dahiya D, Naik A. Gossypiboma: case report and review of literature. *Int. Surg. J.* 2019;6:4148–4151. doi:10.18203/2349-2902.isj20195142. [DOI](#)
- Alemu BN, Tiruneh AG. Gossypiboma: a case series and literature review. *Ethiop. Ethiop J Health Sci.* 2020;30(1):147–149. doi: 10.4314/ejhs.v30i1.19. [DOI](#)
- Szymocha M, Pacan M, Anufrowicz M et al. Leaving a foreign object in the body of a patient during abdominal surgery: still a current problem. *Pol Przegl Chir.* 2019;91(6):35–40. doi: 10.5604/01.3001.0013.2024. [DOI](#)
- American College of Surgeons (ACS) Committee on Perioperative Care Revised statement on the prevention of unintentionally retained surgical items after surgery. *Bull. Am. Coll. Surg.* 2016;101:50(10)-51.
- Ambulkar R, Ranganathan P, Salunke K, Savarkar S. The World Health Organization Surgical Safety Checklist: An audit of quality of implementation at a tertiary care high volume cancer institution. *J Anaesthesiol Clin Pharmacol.* 2018;34(3):392–398. doi: 10.4103/joacp.JOACP_328_17. [DOI](#)
- Fencil JL. Guideline implementation: prevention of retained surgical items. *AORN J.* 2016;104(1):37–48. doi: 10.1016/j.aorn.2016.05.005. [DOI](#)

CONFLICT OF INTEREST

The Authors declare no conflict of interest

CORRESPONDING AUTHOR

Oleh H. Krasnov

Poltava State Medical University

23 Shevchenko Street, 36011, Poltava, Ukraine

e-mail: krasnovoleh0601@gmail.com

ORCID AND CONTRIBUTIONSHIP

Mykola I. Kravtsiv: 0000-0002-9602-4714 **A B D E F**
Maxym O. Dudchenko: 0000-0002-6897-0383 **A B D E F**
Dmytro M. Ivashchenko: 0000-0001-7344-4129 **A B E**
Mykola P. Shevchuk: 0000-0002-8115-7645 **B D E**
Oleh H. Krasnov: 0000-0002-8704-1686 **D F**
Tamara V. Horodova-Andrieieva: 0000-0002-4093-5607 **E**
Olexandr M. Liulka: 0000-0002-1056-8308 **B**

A – Work concept and design, **B** – Data collection and analysis, **C** – Responsibility for statistical analysis, **D** – Writing the article, **E** – Critical review, **F** – Final approval of the article

RECEIVED: 14.06.2024

ACCEPTED: 23.01.2025

