

# Cervical myelopathy after neglected, minor cervical spine injury: the importance of early and continuous rehabilitation – case report

Paweł Mamczarz<sup>1</sup>, Jędrzej Kęsik<sup>1</sup>, Mateusz Trubalski<sup>1</sup>, Jakub Kłohsek<sup>1</sup>, Aleksandra Kaźmierczyk<sup>1</sup>, Karolina Turżańska<sup>2</sup>, Nataliia Fedorenko<sup>2</sup>, Joanna Niezbecka-Zajac<sup>2</sup>, Małgorzata Drelich<sup>2</sup>, Wojciech Kłapeć<sup>2</sup>


<sup>1</sup>STUDENT SCIENTIFIC ASSOCIATION AT THE DEPARTMENT OF REHABILITATION AND ORTHOPEDICS, MEDICAL UNIVERSITY OF LUBLIN, LUBLIN, POLAND

<sup>2</sup>DEPARTMENT OF REHABILITATION AND ORTHOPEDICS, MEDICAL UNIVERSITY OF LUBLIN, LUBLIN, POLAND

## ABSTRACT

Degenerative cervical myelopathy (DCM) is adults' most common form of spinal cord injury. Its clinical symptoms result from spinal cord compression due to acute and chronic spinal column processes. However, DCM's exact pathophysiology is uncertain. Due to difficulty in diagnosis, many patients suffering from DCM remains undiagnosed until the symptoms become debilitating. The subject of this study is a 42-year-old male with no previous medical history. Neurological symptoms suddenly appeared three months prior to the hospital admission. An MRI revealed hernias of intervertebral discs between C4-C5, C5-C6, and C6-C7 and myelopathy in the most compressed parts of the spinal cord (C4-C5-C6 level). Cervical spondylodesis from anterior access, C3-C6 laminectomy, and spinal decompression were performed. The patient's postoperative symptoms worsened suddenly with the presence of tetraparesis. After prolonged rehabilitation, satisfactory motor function was regained. No possible cause for the development of myelopathy was apparent, although the patient recalled experiencing an injury 20 years earlier. Despite cervical injuries being challenging to diagnose and presenting no clinical symptoms at first, an almost complete recovery after the late onset of symptoms is possible with proper surgical treatment and rehabilitation.

**KEY WORDS:** cervical myelopathy, minor cervical injury, neurorehabilitation, exercise, rehabilitation

Wiad Lek. 2025;78(3):643-650. doi: 10.36740/WLek/202334 

## INTRODUCTION

Cervical spine injuries rank among the frequently occurring fractures of the skeletal system, often linked to diminished bone density and other factors contributing to skeletal vulnerability. They occur in 1.5% to 7.7% of all major trauma cases, with the highest prevalence in 15-24-year-old males. The most common causes are car accidents (42% to 56%), falls (19-30%), as well as sports-related activities, and gunshot wounds (6-7%). Vehicle accidents often occur for younger patients, whereas falls are most common for older people [1, 2]. The spinal injury is considered neglected when not treated for over three weeks. When an injury is missed, the possible consequences include the risk of progressive instability, also associated with ligament damage and neurological deterioration [3,4]. Overlooked spinal injuries are the most common in the cervical spine compared with the thoracolumbar spine and sacrum [5]. According to the literature, the rate of

undiagnosed injuries ranges from 4% to 30%, with the most commonly cited reasons for this are inadequate radiological examination [6], misinterpretation of radiographs, and inappropriate or inadequate physical/neurological examination due to associated injuries in polytrauma patients. In the absence of neurological symptoms, the patients themselves disregard the minor or moderate cervical trauma, unaware of the possible secondary consequences. For developing countries, poor accessibility to healthcare is also a factor [7].

Delayed diagnosis of such injuries may result in progressive kyphotic deformity, pain, and even progressive neurologic deficit. Up to 10% of patients with cervical column injury who initially had no neurologic deficit deteriorated after admission to a trauma center [8]. In milder cases, prolonged instability can lead to overload-degenerative and discopathic changes, kyphotization, and, consequently, spinal cord compression.

Degenerative cervical myelopathy (DCM) is adults' most common form of spinal cord injury. It involves spinal cord dysfunction from compression. Patients usually report gradually increasing symptoms such as pain and numbness in limbs, poor coordination, and imbalance [9, 10]. The exact pathophysiology underlying DCM remains uncertain. Clinical symptoms generally result from spinal cord compression secondary to many factors. It can occur due to disk herniation, infoldings of ligamentum flavum and facet joint capsule, or canal stenosis. It may compress and damage the surrounding vascular and neural structures, contributing to disease severity. These various mechanisms leading to compression are classified as either static or dynamic mechanical. Static risk factors are constant and result in direct injury via stenosis of the cervical canal. Dynamic factors involve repetitive injury, typically arising from flexion or extension of the cervical spine. It can stretch the axons, making them more susceptible to secondary injury [11]. The epidemiology of DCM is poorly understood, partly because of the difficulties in diagnosis [3]. Diagnosing DCM and assessing its prevalence may be difficult because its development is different for each patient, which depends on the interaction between time, mechanical load, and individual predisposition to spinal cord injuries [12]. It accounts for 54% of nontraumatic spinal cord injuries in the US, with an incidence of 76 per million. 10% of all patients aged 55 and over demonstrate clinical DCM, although 50% of patients in this age group demonstrate radiographic evidence of cervical spondylosis in MRI [13]. The prevalence of surgically treated DCM is estimated at 1.6 *per* 100,000 inhabitants (actual prevalence is suspected to be much higher). Many patients with DCM remain undiagnosed. A small study of 66 patients with hip fractures found 18% of patients who were previously undiagnosed had clinical findings suggestive of DCM [14]. The diagnosis of DCM is mainly made based on magnetic resonance imaging (MRI) [15]. MRI is a gold standard in confirming the diagnosis of DCM [16]. This examination enables the detection of spinal cord compression in the cervical region [15]. The diagnosis is also based on the neuralgic symptoms reported by the patient. Typical examination results may involve neck discomfort or rigidity, an unsteady walking pattern with a broad base, tingling sensations increasing in the upper or lower limbs, weakness in the lower limbs, reduced manual dexterity, heightened reflexes, clonus, the presence of the Babinski sign, and in severe cases, impaired bowel or bladder function. A conclusive diagnosis necessitates aligning the observed physical examination outcomes with corresponding imaging

results. A typical symptom of DCM is pain in the upper limbs (86% of patients with DCM) and neck [17].

Once DCM is diagnosed, the primary decision to be made is whether to manage the condition operatively or nonoperatively [11] initially. Nonoperative interventions, including medications, immobilization with orthotics, physical therapy, and spinal injections, are sometimes recommended for patients with mild symptoms. However, there is little data to support this [13]. The goals of surgery for patients with DCM include decompression of the spinal cord, restoration of cervical alignment, and treatment of instability if present. The prospective AOSpine DCM North America study indicated that cervical decompression arrests deterioration and improves neurological outcomes, functional status, and quality of life (QOL) in patients, regardless of disease severity. Several surgical approaches have been developed to treat DCM, and controversy exists regarding which operation offers the best clinical outcome with the fewest complications. Standard anterior techniques include discectomy, corpectomy, and fusion. Posterior operations include laminectomy, fusion, and laminoplasty. It is now becoming clear that the complex presentation and pathology of patients with DCM call for treatments tailored to specific anatomic and pathologic factors [13]. DCM is generally considered a surgical disease, as it has been found that with nonoperative treatment, the rates of significant activities of daily life impairments are 6% at one year, 21% at two years, 28% at three years, and 56% at ten years [11].

Data from the available literature shows that patients with DCM first refer to general practitioners. However, since DCM is difficult to diagnose, it often takes up to two years to diagnose correctly [17]. Furthermore, extending the appropriate treatment time may negatively affect the effectiveness of DCM treatment [18]. As mentioned earlier, the number of people suffering from DCM is unknown, but it is assumed that the frequency of this disease will increase with the aging of the population [18]. The lack of a correct diagnosis is often associated with poor knowledge about this disease. Making an incorrect diagnosis result in inappropriate treatment, which is crucial in DCM therapy [9, 17].

## AIM

Therefore, this paper presents the case of a patient who suffers from DCM, how the diagnosis was made, what treatment was applied, and whether the patient's condition improved. Presenting the available knowledge in practice will make it easier to understand this disease.

## CASE REPORT

### PATIENT

This study centers on a 42-year-old Caucasian man with no notable medical background and noticeable trauma history. About three months before being admitted to the hospital, the patient suddenly developed tremors in his right foot while crossing a street. Following this incident, the patient complained of numbness in the right upper limb, weakness in the right extremities, tingling on the left side, and noticeable shaking of the right foot. Due to these symptoms, the patient sought advice from a neurologist.

### INITIAL TREATMENT

The patient was directed to the hospital for a comprehensive evaluation. Following this, an extensive physical examination and imaging studies were performed, with Magnetic Resonance Imaging (MRI) for a more detailed analysis. An MRI has revealed a complete loss of physiological cervical lordosis with a small kyphosis at the C4-C5-C6 level, right-sided extrusion of intervertebral discs between C4-C5, C5-C6, and C6-C7 vertebrae and rupture of annulus fibrosus on the C4-C5 level and the focal myelopathy in the most compressed parts of the spinal cord (C4-C5-C6 level).

### THE SURGERY

Following the examination, the patient was directed to the Department of Neurosurgery (Fig. 1). Two days later, procedures including cervical spondylodesis through anterior access, C3-C6 laminectomy, and spinal decompression were carried out [19].

Another neurosurgery procedure, involving anterior decompression of the cervical spine, was scheduled for four months later.

### REHABILITATION

Eight days post-surgery, the patient was transferred to the Rehabilitation Department where a 26-day stay ensued. Upon admission, the patient exhibited tetraparesis, particularly pronounced on the right side, affecting the upper limbs and distal parts of the body, leading to complete paralysis of the III-V fingers of the right hand.

During the stay in the Rehabilitation Department, the patient underwent a comprehensive treatment regimen, encompassing patient tailored individual physiotherapy with the special focus on neurodevelopmental therapy, locomotor therapy, balance and coordination exercises and additional modalities such as hydrothera-

py, electrostimulation, magnetic field therapy, occupational therapy, and psychological therapy. The primary objectives of these interventions were to enhance the patient's mobility, self-care abilities, and facilitate the performance of precision tasks [20]. Steady improvement was observed throughout the hospitalization, with the patient achieving the capability to walk with crutches, engage in self-care, and feed independently. However, precision tasks remained challenging at the time of discharge.

### AFTER HOSPITALIZATION

Upon leaving the hospital, the patient continued to receive comprehensive rehabilitation care in the outpatient unit. Twenty-seven days post-discharge, the patient achieved the ability to walk on short distances without crutches and perform tasks requiring precision, although muscle strength in the upper limb remained diminished, hindering the lifting of heavy objects. Uncontrollable spasms in the right lower limb occurred during stress or exhaustion, and reduced sensation persisted in areas of the right arm innervated by the medial cutaneous nerve of the forearm and ulnar nerve. Additionally, there was an inability to fully actively straighten the IV and V fingers of the right hand.

Three months after leaving the hospital, patient continued rehabilitation sessions. The patient's walking ability further improved, and he could perform daily tasks requiring hand dexterity, including cooking and minor home repairs. Control MR showed: Sagittal T2-weighted images showed reversal of physiological cervical lordosis with kyphotic positioning. The preservation of the vertebral bodies height with sharpening at the edges. Dehydration and reduced height of the inter vertebral discs at the levels C4/C5, C5/C6 and C6/C7. A clear intrathecal displacement of the intervertebral disc at the C4/C5, C5/C6 and C6/C7 levels with significant pressure on the dural sac, and additionally with pressure on the ventral surface of the spinal cord at the C5/C6 level. At the C4/C5 level in the spinal cord, a high-signal area – myelopathy.

Despite the MR results due to significant functional improvement, a conducted follow-up lead the attending neurosurgeon to postpone the scheduled anterior decompression surgery for several months. Six months post-discharge, continuous rehabilitation efforts resulted in efficient walking without assistance, and hand function continued to improve. Following another neurosurgical evaluation, the surgery was postponed indefinitely, and the patient remains under constant supervision (Fig. 2).

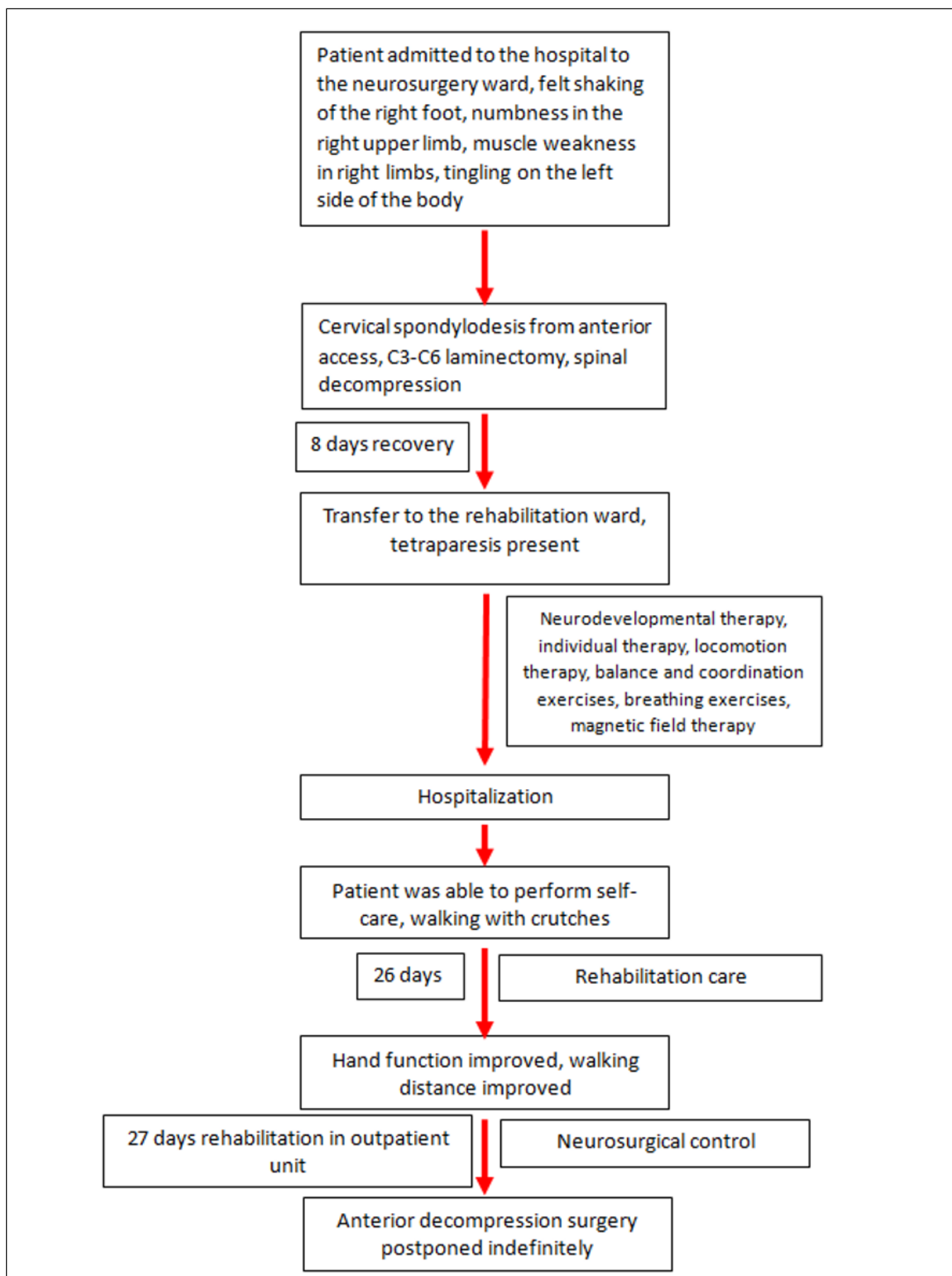
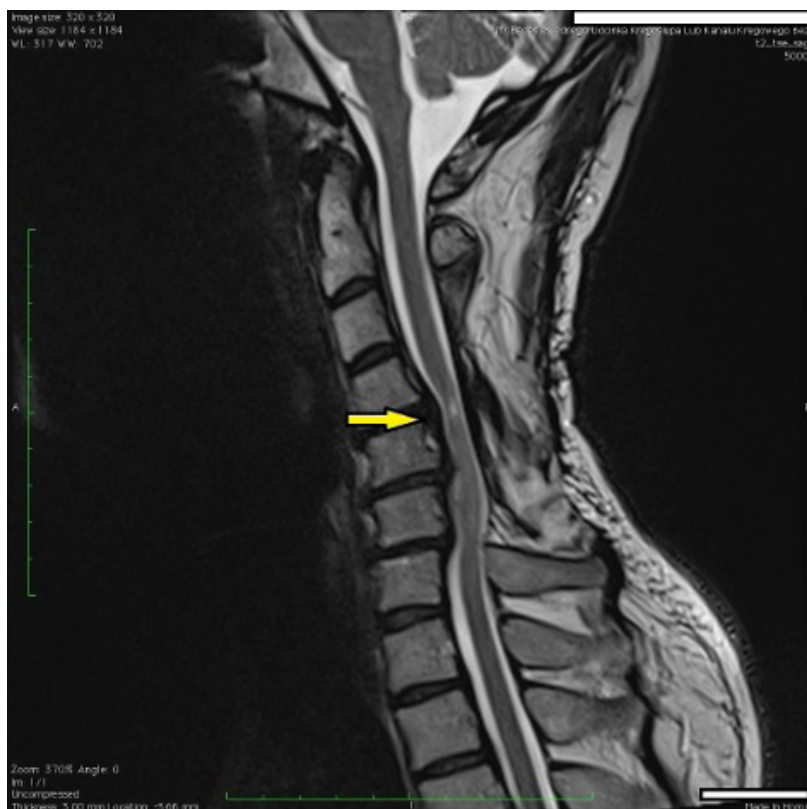

Fig. 1. Course of treatment.



**Fig. 2.** Sagittal T2-weighted images showed reversal of physiological cervical lordosis with kyphotic positioning. The preservation of the vertebral bodies height with sharpening at the edges. Dehydration and reduced height of the inter vertebral discs at the levels C4/C5, C5/C6 and C6/C7. A clear intrathecal displacement of the intervertebral disc at the C4/C5, C5/C6 and C6/C7 levels with significant pressure on the dural sac, and additionally with pressure on the ventral surface of the spinal cord at the C5/C6 level. At the C4/C5 level in the spinal cord, a high-signal area – myelopathy (arrow).

## PROBABLE CAUSE OF THE DEVELOPMENT OF MYELOPATHY

Initially, the patient had no memory of a potential trigger for the onset of myelopathy. Upon thorough reflection on past experiences, he recalled an injury (a fall from a height) that occurred two decades earlier during his military service. At the time, he downplayed its significance and did not seek medical assistance. Following the fall, he experienced temporary cervical radiculopathy, which he dismissed. Subsequent intermittent symptoms were personally attributed by him to a sedentary lifestyle.

## DISCUSSION

Injuries to the cervical spine occur in approximately 3% of patients with major trauma and 10% of patients with serious head injuries [21]. Cervical spine injuries may result from not only major vehicle accidents or falls from a height but also low-velocity collisions in a whiplash mechanism. These kinds of injuries can cause damage to the facet capsule, intervertebral discs, and lead to muscles stretch injury and ligamentous elements of the cervical spine which may result in future instability of the cervical spine [22]. Cervical spine injuries without immediate neurological symptoms are easily missed by clinicians, often leading to a delay in diagnosis. Their

overall incidence varies between 4 and 30% [5]. The initial diagnosis of cervical spine injury should rely on proper patient selection on a clinical basis, obtaining appropriate radiological study, and most crucially properly interpreting them [23]. Neglected and overlooked upper spine injuries such as the one presented in this report often lead to long-term consequences which may develop after decades from the injury. Nonoperative treatment may be offered only to asymptomatic patients, although a systematic review analyzing patients with DCM who were treated nonoperatively found that 20% to 60% of patients had neurological deterioration within 3-6 months [22]. Thus, surgical intervention is considered to be the only effective solution for patients with mild or severe symptoms. Degenerative spine myelopathy (DCM) is known for its progressive neurological dysfunction and potential mortality; therefore, it is crucial not to ignore even mild asymptomatic injuries to the cervical spine and comprehensively examine every trauma patient [24].

Turning our attention to the case under discussion, the patient exhibited symptoms characteristic of Degenerative Cervical Myelopathy (DCM). The reported symptoms included numbness in the right foot and right upper limb, tingling on the left side of the body, trembling of the right foot, and weakness in the muscles of the right limbs. An MRI was conducted, revealing a reduction in the normal cervical lordosis with a tenden-

cy towards kyphosis at the C4-C5-C6 level, right-sided intervertebral disc herniations between C4-C5, C5-C6, C6-C7, a rupture of the annulus fibrosis at the C4-C5 level, and focal myelopathy in the most compressed segment of the spinal cord (levels C4-C5-C6) [25, 26].

As per the literature, approximately one-third of patients experience significant improvement post-surgery. Conversely, around 40% of surgeries yield no discernible results. On the contrary, the condition of up to 25% of patients deteriorates after surgery [24, 27]. In contrast, other studies report neurological decline in DCM patients post-surgery in 7% to 11% of cases [28, 29].

Some studies suggest that improvement after operation occurs more often in patients who, did not smoke, had less severe symptoms of DCM (no gait disturbance) and did not have additional comorbidities and most significantly had a short waiting time for the procedure [30], which is supported by results of recent studies show that the best results after surgery are achieved by patients in whom the time between the procedure and the first symptoms of DCM is shorter than 4 months [31, 32].

In this case, the patient smoked only occasionally in his youth and had no comorbidities. The most probable cause of DCM development was the injury that occurred 20 years earlier (fall from height). The patient disregarded transient cervical radiculopathy. Later symptoms from the nervous system were attributed by the patient to a sedentary lifestyle. The patient came to the doctor only when the symptoms intensified, so that he was unable to function normally. We hypothesized that this delay, severity of symptoms with corresponding changes within the spina were the key factors that could have influenced the outcome of the operation.

After 8 days of hospitalization in the neurosurgery and department. The patient was transferred to the rehabilitation department. Appropriate treatment was immediately implemented. As a result, after 26 days of hospitalization, the patient regain partially ability to walk with crutches, feed himself and perform self-service activities, but he was unable to perform activities requiring precision. After discharged, patient continued rehabilitation, which resulted in a significant improvement. 27 days after discharge, he was able to walk short distances without crutches and the function of the

hands improved. As a result of systematic rehabilitation of the patient the improvement of neuralgic condition was observed through the reduction of symptoms, and these changes were confirmed by MRI. The achieved improvement made it possible to postpone the reoperation indefinitely.

In this instance, we observe the crucial role of early and suitable rehabilitation for patients facing complications after undergoing surgical treatment for Degenerative Cervical Myelopathy (DCM). Nevertheless, the existing literature lacks comprehensive research assessing the impact of rehabilitation on the recovery of individuals with DCM [33, 34], as the disease has only recently garnered attention from scientists. Additionally, epidemiological data remains incomplete, owing to the challenging diagnosis of this condition. Nonetheless, it is well-established that implementing rehabilitation for all disabled patients leads to significant improvements not only in their functional status but also in their overall well-being and independence. Rehabilitation also holds importance in postoperative care, aiding in the prevention of issues associated with the surgical procedure, such as reducing the risk of neuropathic pain, spasticity, osteoporosis, cardiovascular diseases, and more [34].




The case of our patient underscores the critical significance of appropriate rehabilitation. However, our study is constrained by its reliance on a single patient case, emphasizing the need for further research in this direction.

## CONCLUSIONS

Young individuals, particularly males, often overlook potentially significant injuries if immediate symptoms are not evident. Consequently, when investigating the origins of myelopathy, it is advisable to conduct a detailed interview and inquire about past injuries, even those that may appear unrelated to the present ailment.

Even in instances of severe complications following surgical treatment for Degenerative Cervical Myelopathy (DCM) and persisting changes in MR findings proper rehabilitation can result in satisfactory outcomes and substantial enhancements in the quality of life for patients. This was affirmed in the case we have discussed. We advocate for further research in this area.

## REFERENCES

- Schousboe JT. Epidemiology of Vertebral Fractures. *J Clin Densitom.* 2016;19(1):8-22. doi:10.1016/j.jocd.2015.08.004 
- Lacy J, Bajaj J, Gillis CC. Atlantoaxial Instability. In: *StatPearls.* Treasure Island (FL): StatPearls Publishing; June 12, 2023.
- Jain AK, Dhammi IK, Singh AP, Mishra P. Neglected traumatic dislocation of the subaxial cervical spine. *J Bone Joint Surg Br.* 2010;92(2):246-249. doi:10.1302/0301-620X.92B2.22963 
- Liao S, Jung MK, Hörnig L, Grützner PA, Kreinest M. Injuries of the upper cervical spine-how can instability be identified? *Int Orthop.* 2020;44(7):1239-1253. doi:10.1007/s00264-020-04593-y 

5. Ifthekar S, Ahuja K, Mittal S, et al. Management of Neglected Upper Cervical Spine Injuries. *Indian J Orthop*. 2020;55(3):673-679. Published 2020 Aug 13. doi:10.1007/s43465-020-00227-y [DOI](#)
6. Jain AK, Dhammi IK, Singh AP, Mishra P. Neglected traumatic dislocation of the subaxial cervical spine. *J Bone Joint Surg Br*. 2010;92(2):246-249. doi:10.1302/0301-620X.92B2.22963 [DOI](#)
7. Srivastava SK, Aggarwal RA, Bhosale SK, Nemade PS. Neglected dislocation in sub-axial cervical spine: Case series and a suggested treatment protocol. *J Craniovertebr Junction Spine*. 2016;7(3):140-145. doi:10.4103/0974-8237.188414 [DOI](#)
8. Sengupta DK. Neglected spinal injuries. *Clin Orthop Relat Res*. 2005;(431):93-103. doi:10.1097/01.blo.0000151878.67386.a1 [DOI](#)
9. Davies BM, Mowforth OD, Smith EK, Kotter MR. Degenerative cervical myelopathy. *BMJ*. 2018;360:k186. Published 2018 Feb 22. doi:10.1136/bmj.k186 [DOI](#)
10. Hakalo J, Wroński J. Powikłania stabilizacji transpedikularnej wybuchowych złamań odcinka piersiowo-lędźwiowego kregosłupa [Complications of a transpedicular stabilization of thoraco-lumbar burst fractures]. *Neurol Neurochir Pol*. 2006;40(2):134-139 [Polish].
11. McCormick JR, Sama AJ, Schiller NC, Butler AJ, Donnally CJ 3rd. Cervical Spondylotic Myelopathy: A Guide to Diagnosis and Management. *J Am Board Fam Med*. 2020;33(2):303-313. doi:10.3122/jabfm.2020.02.190195 [DOI](#)
12. Davies BM, Stubbs D, Gillespie CS, et al. Life expectancy in patients with degenerative cervical myelopathy is currently reduced but can be restored with timely treatment. *Acta Neurochir (Wien)*. 2023;165(5):1133-1140. doi:10.1007/s00701-023-05515-8 [DOI](#)
13. Iyer A, Azad TD, Tharin S. Cervical Spondylotic Myelopathy. *Clin Spine Surg*. 2016;29(10):408-414. doi:10.1097/BSD.0000000000000397 [DOI](#)
14. Radcliff KE, Curry EP, Trimba R, et al. High Incidence of Undiagnosed Cervical Myelopathy in Patients With Hip Fracture Compared With Controls. *J Orthop Trauma*. 2016;30(4):189-193. doi:10.1097/BOT.0000000000000485 [DOI](#)
15. Lannon M, Kachur E. Degenerative Cervical Myelopathy: Clinical Presentation, Assessment, and Natural History. *J Clin Med*. 2021;10(16):3626. Published 2021 Aug 17. doi:10.3390/jcm10163626 [DOI](#)
16. Joaquim AF, Ghizoni E, Tedeschi H, Hsu WK, Patel AA. Management of degenerative cervical myelopathy – An update. *Rev Assoc Med Bras (1992)*. 2016;62(9):886-894. doi:10.1590/1806-9282.62.09.886 [DOI](#)
17. Milligan J, Ryan K, Fehlings M, Bauman C. Degenerative cervical myelopathy: Diagnosis and management in primary care. *Can Fam Physician*. 2019;65(9):619-624.
18. Kane SF, Abadie KV, Willson A. Degenerative Cervical Myelopathy: Recognition and Management. *Am Fam Physician*. 2020;102(12):740-750.
19. Huang M, Gao X, Cheng J, Han J, Liu J. Laminoplasty versus laminectomy and fusion for multilevel cervical compressive myelopathy: A meta-analysis [published correction appears in *Medicine (Baltimore)*. 2016 Jul 18;95(28):e0916. doi: 10.1097/01.md.0000489580.04709.16]. *Medicine (Baltimore)*. 2016;95(23):e03588. doi:10.1097/MD.00000000000003588 [DOI](#)
20. Dolkart O, Kazum E, Rosenthal Y, et al. Effects of focused continuous pulsed electromagnetic field therapy on early tendon-to-bone healing. *Bone Joint Res*. 2021;10(5):298-306. doi:10.1302/2046-3758.105.BJR-2020-0253.R2 [DOI](#)
21. Gerrelts BD, Petersen EU, Mabry J, Petersen SR. Delayed diagnosis of cervical spine injuries. *J Trauma*. 1991;31(12):1622-1626. doi:10.1097/00005373-199112000-00010 [DOI](#)
22. Williams J, D'Amore P, Redlich N, et al. Degenerative Cervical Myelopathy: Evaluation and Management. *Orthop Clin North Am*. 2022;53(4):509-521. doi:10.1016/j.ocl.2022.05.007 [DOI](#)
23. Chen HB, Yang KH, Wang ZG. Biomechanics of whiplash injury. *Chin J Traumatol*. 2009;12(5):305-314.
24. Badhiwala JH, Witiw CD, Nassiri F, et al. Efficacy and Safety of Surgery for Mild Degenerative Cervical Myelopathy: Results of the AOSpine North America and International Prospective Multicenter Studies. *Neurosurgery*. 2019;84(4):890-897. doi:10.1093/neuros/nyy133 [DOI](#)
25. Lebl DR, Hughes A, Cammisa FP Jr, O'Leary PF. Cervical spondylotic myelopathy: pathophysiology, clinical presentation, and treatment. *HSS J*. 2011;7(2):170-178. doi:10.1007/s11420-011-9208-1 [DOI](#)
26. Tetreault L, Palubiski LM, Kryshtalskyj M, et al. Significant Predictors of Outcome Following Surgery for the Treatment of Degenerative Cervical Myelopathy: A Systematic Review of the Literature. *Neurosurg Clin N Am*. 2018;29(1):115-127.e35. doi:10.1016/j.nec.2017.09.020 [DOI](#)
27. Kalsi-Ryan S, Karadimas SK, Fehlings MG. Cervical spondylotic myelopathy: the clinical phenomenon and the current pathobiology of an increasingly prevalent and devastating disorder. *Neuroscientist*. 2013;19(4):409-421. doi:10.1177/1073858412467377 [DOI](#)
28. Kato S, Fehlings M. Degenerative cervical myelopathy. *Curr Rev Musculoskelet Med*. 2016;9(3):263-271. doi:10.1007/s12178-016-9348-5 [DOI](#)
29. Badhiwala JH, Ahuja CS, Akbar MA, et al. Degenerative cervical myelopathy – update and future directions. *Nat Rev Neurol*. 2020;16(2):108-124. doi:10.1038/s41582-019-0303-0 [DOI](#)
30. Tetreault L, Kopjar B, Côté P, Arnold P, Fehlings MG. A Clinical Prediction Rule for Functional Outcomes in Patients Undergoing Surgery for Degenerative Cervical Myelopathy: Analysis of an International Prospective Multicenter Data Set of 757 Subjects. *J Bone Joint Surg Am*. 2015;97(24):2038-2046. doi:10.2106/JBJS.0.00189 [DOI](#)

31. Munro CF, Yurac R, Moritz ZC, et al. Targeting earlier diagnosis: What symptoms come first in Degenerative Cervical Myelopathy? *PLoS One*. 2023;18(3):e0281856. Published 2023 Mar 31. doi:10.1371/journal.pone.0281856 [DOI](#)
32. Tetreault L, Wilson JR, Kotter MRN, et al. Is Preoperative Duration of Symptoms a Significant Predictor of Functional Outcomes in Patients Undergoing Surgery for the Treatment of Degenerative Cervical Myelopathy? *Neurosurgery*. 2019;85(5):642-647. doi:10.1093/neuros/nyy474 [DOI](#)
33. Badran A, Davies BM, Bailey HM, Kalsi-Ryan S, Kotter MR. Is there a role for postoperative physiotherapy in degenerative cervical myelopathy? A systematic review. *Clin Rehabil*. 2018;32(9):1169-1174. doi:10.1177/0269215518766229 [DOI](#)
34. Boerger TF, Hyngstrom AS, Furlan JC, et al. Developing Peri-Operative Rehabilitation in Degenerative Cervical Myelopathy [AO Spine RECODE-DCM Research Priority Number 6]: An Unexplored Opportunity? *Global Spine J*. 2022;12(1\_suppl):97S-108S. doi:10.1177/21925682211050925 [DOI](#)

### CONFLICT OF INTEREST

The Authors declare no conflict of interest.

### CORRESPONDING AUTHOR

**Mateusz Trubalski**

Student Scientific Association  
at the Department of Rehabilitation and Orthopedics  
Medical University of Lublin  
Lublin, Poland  
e-mail: mateusztrub@gmail.com

### ORCID AND CONTRIBUTIONSHIP

Paweł Mamczarz: 0009-0000-5684-2985 [A](#) [B](#) [D](#)  
Jędrzej Kęsik: 0000-0001-8317-0213 [A](#) [B](#) [D](#)  
Mateusz Trubalski: 0000-0002-2656-5398 [A](#) [B](#) [D](#)  
Jakub Kłohsek: 0009-0009-9644-3538 [A](#) [B](#) [D](#)  
Aleksandra Kaźmierczyk: 0009-0007-7283-2518 [A](#) [B](#) [D](#)  
Karolina Turżańska: 0000-0001-7359-9622 [A](#) [B](#) [E](#) [F](#)  
Nataliia Fedorenko: 0000-0001-5306-2991 [B](#) [E](#) [F](#)  
Joanna Niezbecka-Zajac: 0000-0001-8591-4490 [E](#) [F](#)  
Małgorzata Drelich: 0000-0001-6709-0440 [E](#) [F](#)  
Wojciech Kłapeć: 0009-0008-1680-5061 [E-F](#)

[A](#) – Work concept and design, [B](#) – Data collection and analysis, [C](#) – Responsibility for statistical analysis, [D](#) – Writing the article, [E](#) – Critical review, [F](#) – Final approval of the article

**RECEIVED:** 23.11.2024

**ACCEPTED:** 12.02.2025

