

Peculiarities of complex oral rehabilitation of young patients with juvenile idiopathic arthritis and malocclusion

Renata V. Symonenko, Leonid O. Etnis, Zinaida Y. Zhehulovych, Vitalii V. Parii, Olena O. Astapenko, Daryna I. Bohatyrova, Iryna M. Fedianovych
BOGOMOLETS NATIONAL MEDICAL UNIVERSITY, KYIV, UKRAINE

ABSTRACT

Aim: The aim of the study was to analyze the efficiency when planning complex oral rehabilitation, conducting proper preparation, occlusal analysis and adjustment during the stages of orthodontic treatment in young patients with Juvenile Idiopathic Arthritis.

Materials and Methods: 11 young patients with diagnosis of Juvenile Idiopathic Arthritis (according to ILAR criteria) aged from 18 to 34 years (mean age 22.64 ± 4.82) who included 6 females and 5 males were examined and underwent orthodontic treatment at Dental Medical Center of Bogomolets National Medical University during 2021-2024 years. The orthodontic treatment was carried out after oral cavity sanitation and elimination of temporomandibular disorders manifestations using occlusal splints and was combined with local medication therapy (mouth rinse using medicinal composition of highly dispersed silica gel and bacteria strains of *Bacillus subtilis* B-7812(AX20) and *Bacillus licheniformis* IMB B-7811(EA22)). Occlusal analysis and adjustments were carried out during all stages of rehabilitation.

Results: Provided orthodontic treatment in combination with application of bite blocks and direct dental hard tissues restorations allowed to expand the dental arches, align the midline and normalize the occlusal contacts of the teeth in static and dynamic occlusion in all patients. There were no signs of premature contacts, occlusal overload, deterioration of periodontal lesion or temporomandibular disorder manifestation recurrence.

Conclusions: Our study showed that the proposed complex rehabilitation of patients with JIA including proper occlusal analysis and adjustment and probiotics usage during orthodontic treatment within the framework of a personalized approach during their rehabilitation ensures minimization of risks and is the key to achieving optimal results.

KEY WORDS: juvenile idiopathic arthritis, dental occlusion, temporomandibular joint, orthodontics, periodontitis

Wiad Lek. 2025;78(4):746-752. doi: 10.36740/WLek/203849 DOI

INTRODUCTION

Juvenile idiopathic arthritis (JIA) is a collective term that combines a number of systemic connective tissue diseases with a currently unclear etiology and a predominant localization of the inflammatory process in the musculoskeletal system, lasting at least 6 weeks and developing in children under 16 years of age. The prevalence of this disease in Ukraine is estimated at 0.37 cases per 1000 children under 17 years of age with a tendency to increase. In total, more than 3000 children with JIA have been registered in Ukraine. The disease has a progressive course, does not end with complete recovery and has a high degree of disability [1, 2]. Therefore, JIA is an important medical and social problem.

In patients with JIA, the clinical situation in most cases becomes comorbid. Therefore, comprehensive rehabilitation of such patients with the involvement of specialists of various profiles is of great importance. Unfortunately, many questions related to the treatment of

patients with JIA still remain unanswered, including the features of complex oral rehabilitation of such patients.

The nature of the course of JIA depends not only on its clinical variant, disease activity and the degree of involvement of certain target organs in the pathological process, but also on the therapy performed, dose, its effectiveness and duration. It is known that most often side effects develop in patients due to prolonged use of glucocorticoids and against the background of the lack of an adequate response to basic disease-modifying synthetic or immunobiological drugs. The use of corticosteroids can increase the risk of root resorption, which may complicate orthodontic movement and the overall stability of teeth after treatment. Drugs like methotrexate can cause mucosal ulcers, dry mouth, or oral infections, which need to be managed during rehabilitation. Patients undergoing Disease-Modifying Anti-Rheumatic Drugs therapy may be more prone to infections or delayed wound healing after dental pro-

cedures. Immunobiological drugs and TNF inhibitors may alter the immune response and increase the risk of periodontal diseases or other oral infections, necessitating close monitoring and care during oral rehabilitation. JIA's activity can fluctuate, so oral rehabilitation plans should remain flexible, with frequent reassessment to adjust treatment plans as needed, based on the patient's rheumatologic status.

In patients with JIA all the joints can be affected, including the temporomandibular joint (TMJ). The incidence of TMJ involvement according to literature data ranges from 17% to 87%, depending on the studied population, JIA subtypes and diagnostic method [3]. In addition to direct inflammatory lesions, deformation of the TMJ and severe pain syndrome, JIA may have an indirect effect on the development of musculoskeletal dysfunctions and occlusal disorders. During the growth and formation of the maxillofacial system, even a minor inflammatory process in the synovial membrane leads to impaired development of the TMJ, which is the growth zone of the lower jaw, which contributes to delayed development of the jaw bones, the formation of incorrect occlusal relationships and as a result leads to further destruction of the articular process of the lower jaw.

During the initial stage of the disease, this manifests itself in the form of dysfunction, which, according to various authors, occurs in 50-94% of patients. During later stages of the disease, muscle weakness, decreased chewing efficiency and limited mobility in the TMJ are being noted [4]. With further damage to the TMJ, the movements of the lower jaw become limited and painful. The patient cannot open his mouth wide and eating becomes difficult. The impaired motor skills due to damage to the musculoskeletal system, pain symptoms, limited mouth opening, possible side effects of drug therapy, limited access to qualified dental care contribute to a decrease in the quality of oral hygiene and negatively affect the patient's oral health. With further progression, the patient cannot open his mouth wide, eating becomes difficult, and oral hygiene deteriorates, which can lead to the development and progression of periodontal tissue lesions and the formation of occlusal pathology [5]. At the same time, mandibular micrognathia – underdevelopment of the lower jaw develops, which leads to the development of malocclusion (in particular, II class by Angle, facial asymmetry), which, can lead to development of periodontal lesions and the formation of occlusal pathology. Semi-retention of the third permanent molars may be often observed in patients with JIA, which can be associated with violations of the mechanism of tooth eruption.

Damage to the temporomandibular joint as well as the presence of chronic inflammation, long-term use

of glucocorticoids and cytostatic therapy in patients with JIA leads not only to orthodontic disorders, but also to a deterioration in the periodontal condition of the patients. Chronic inflammation, medications, and limited oral hygiene due to pain or jaw restrictions can make patients with JIA more susceptible to periodontal disease. Periodontitis is caused by a group of periodontal pathogenic microorganisms, and its continuation depends on the inflammatory and immune reactions of the body that can be induced by JIA. According to the literature, laboratory diagnostics of the levels of IL-1, IL-6 and IL-17, MMP-8 and tumor necrosis factor α (TNF- α) is an important characteristic of the course and an indicator of the effectiveness of treatment of systemic connective tissue diseases, in particular juvenile idiopathic arthritis, which is often a comorbid background for the development of periodontal diseases [6].

Elimination of occlusal disorders at a young age can eliminate or reduce the clinical manifestations of TMJ dysfunction as well as reduce the clinical manifestations of masticatory muscle parafunctions and normalize the muscle's activity. The combination of therapeutical, surgical, orthodontic and prosthetic methods allows to reach the best results of complex rehabilitation [7, 8].

That's why the patients with JIA require a personalized approach and special tactics for treatment of dental pathology as important part of complex rehabilitation. This is especially important for the treatment of young patients with malocclusion, since such patients, against the background of systemic damage to connective tissue and reduced bone mineralization during tooth movement, have an increased risk of developing complications from periodontal tissues, as well as accelerated bone resorption.

AIM

The aim of the study was to demonstrate the importance and analyze the efficiency of considering the general somatic status and bone tissue condition in young patients with Juvenile Idiopathic Arthritis when planning complex oral rehabilitation, conducting proper occlusal analysis and adjustment during at the stages of treatment to minimize possible risks and achieve optimal results.

MATERIALS AND METHODS

11 young patients with diagnosis of Juvenile Idiopathic Arthritis (according to International League of Associations for Rheumatology criteria) and malocclusion aged from 18 to 34 years (mean age 22.64 ± 4.82) who included 6 females and 5 males were examined and

underwent orthodontic treatment at Dental Medical Center of Bogomolets National Medical University during 2021–2024 years. The patients with skeletal severe forms of dentofacial deformities, ankyloses and severe temporomandibular disorders were excluded from the study.

In order to plan the treatment and monitor its effectiveness in addition to the generally accepted clinical examination and orthopantomography, the results of dual-energy X-ray absorptiometry obtained using the Hologic Discovery DXA System, analysis of jaw bone density according to cone-beam computed tomography obtained using the MyRay Hyperion X9 PRO 3D/2D tomograph were analyzed. Digital occlusal analysis was performed with Medit Occlusion Analyzer v.1.02 software using intraoral scans of the jaws and bite records obtained with Medit i500 intraoral scanner.

All the patients during the pre-orthodontic stage of treatment were introduced to basic oral hygiene skills and underwent professional oral hygiene using an ultrasonic apparatus complex. Also all the patients underwent the sanitation of oral cavity including caries treatment, replacement of inappropriate direct restorations, periodontal treatment and extraction of impacted third molars when it was necessary.

The orthodontic treatment was applied in case of absence or after elimination of temporomandibular disorders manifestations using mandibular miorelaxing and stabilizing occlusal splints. It included the expansion of the dental arches of the upper and lower jaws, normalization of the position of the teeth using low forces and fixed orthodontic appliances (a bracket system using a straight arch, starting from 12) with subsequent restoration of the abraded hard tissues of the teeth and final correction of the occlusal relationships based on the data of the occlusal analysis at the final stage of rehabilitation. In order to prevent bone resorption and complications from periodontal tissues it was recommended to use low forces and conduct control examinations and corrections at intervals of 2 weeks. After the expansion of the dental arches, in order to normalize the occlusal relationships in statics and dynamics, a repeated intraoral scan with occlusal analysis was performed and occlusal overlays first to the first premolars of the upper jaw, and then to the second molars, as well as direct restoration of the abraded tooth tissues was carried out. Occlusal analysis and adjustments were carried out every 4 weeks during active teeth movement stage and every 2 weeks at the final stage of rehabilitation.

Orthodontic treatment was combined with local medication therapy in the form of mouth rinse using proposed medicinal composition of highly dispersed silica

gel and bacteria strains of *Bacillus subtilis* B-7812 (AX20) and *Bacillus licheniformis* IMB B-7811 (EA22) (1g of the mixture contains silica gel and 2.5×10^9 CFU of live microbial cells in equal parts). Patients diluted the mixture with boiled water in a ratio of 1 to 10 and rinsed oral cavity once a day during the entire treatment period. In order to analyze the efficiency of probiotics usage, periodontal and oral hygiene status was evaluated using Russell's Periodontal Index (PI) and Greene-Vermillion Simplified Oral Hygiene Index (OHI-S), which were calculated before and after orthodontic treatment.

RESULTS

The study revealed that the caries prevalence among examined patients was 100%, mean DMFT index was 8.75 ± 4.94 . Overall periodontitis prevalence was 100%, while only 4 (21%) had severe periodontitis. All patients shown certain signs of traumatic occlusion such as gingival recessions, abfractions or pathological mobility of teeth of I-II degree. 2 patients (18%) had I class bite, 6 patients (55%) - II class bite, 3 patients (27%) - III class bite. 9 patients (82%) had teeth crowding. 8 patients (73%) had signs of TMJ disorders such as clicking, decreased mouth open or pain.

The results of X-ray absorption densitometry indicated that 8 patients (73%) had osteoporosis and osteopenia. When analyzing cone-beam computed tomography, a significant decrease in the radiological density of the spongy substance of the alveolar processes of the upper (119.99 ± 105.01 Hounsfield units) and lower (227.01 ± 150.67 Hounsfield units) jaws was detected, while the density of the cortical bone on the upper (1550.55 ± 117.33 Hounsfield units) and lower (1932.86 ± 152.92 Hounsfield units) jaws was high.

Digital occlusal analysis revealed that 9 patients (82%) had premature contacts in maximal intercuspal position, 6 patients (55%) – during protrusion and 7 patients (64%) – during laterotrusion.

Positive changes in the position of the TMJ condyles, confirmed by CBCT, were observed in all patients after the use of occlusal splints. These changes served as an indicator for progressing to the next stage of dental treatment, including orthodontic correction. Occlusal equilibration and the normalization of occlusal contact balance were successfully achieved in all patients (Fig. 1).

Provided orthodontic treatment in combination with application of bite blocks and direct dental hard tissues restorations allowed to expand the dental arches, align the midline and normalize the occlusal contacts of the teeth in static and dynamic occlusion in all patients (Fig. 2).

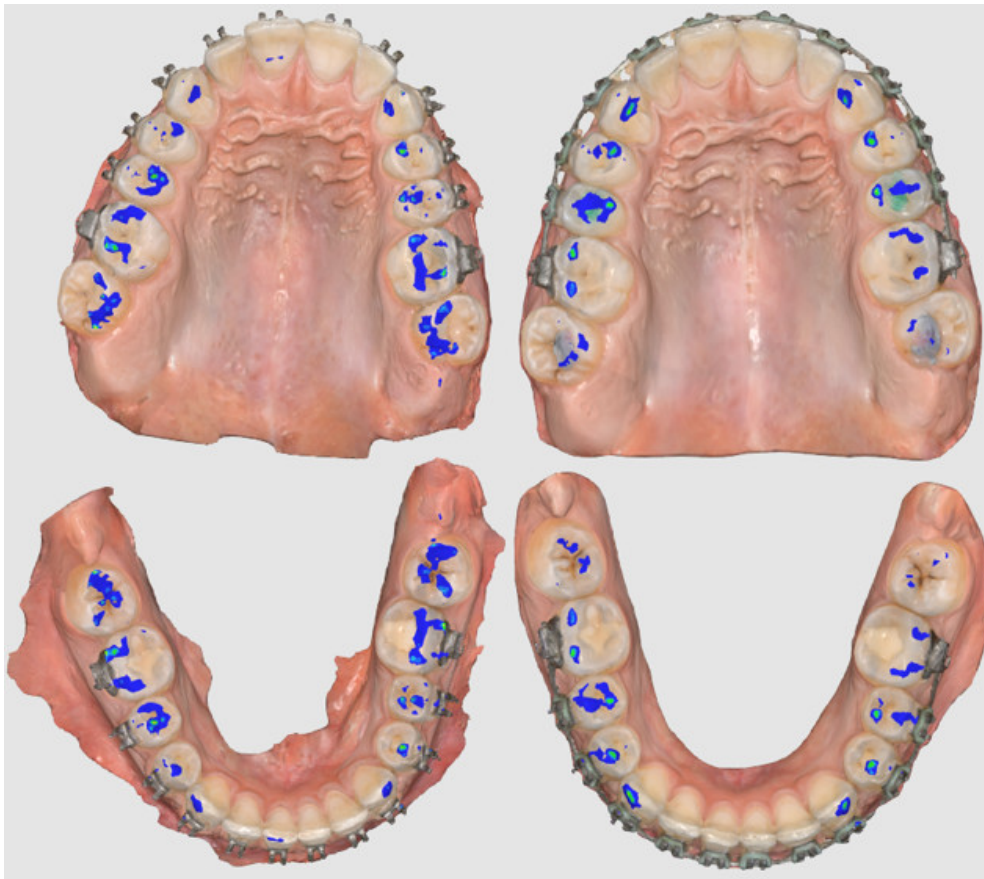


Fig. 1. Dynamics of occlusal contacts changes during the stages of complex oral rehabilitation of a patient with JIA and malocclusion.

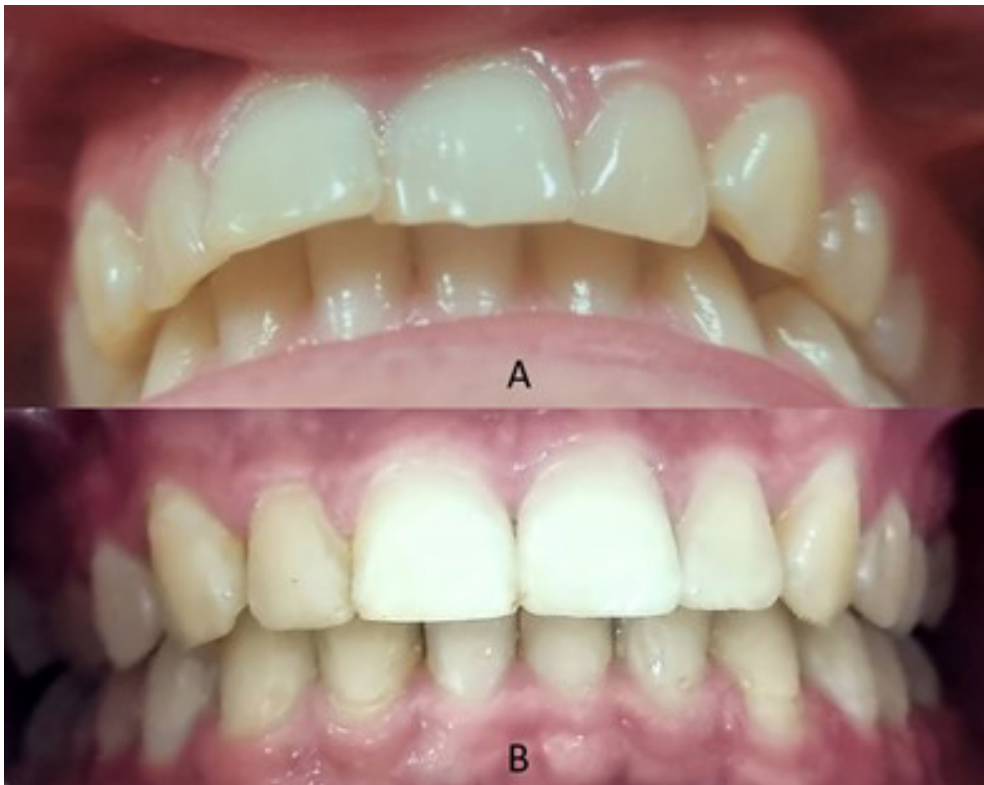

Fig. 2. Dental rows of a patient with JIA and malocclusion before (A) and after (B) complex oral rehabilitation.

There were no signs of premature contacts, occlusal overload, deterioration of periodontal lesion or temporomandibular disorder manifestation recurrence. A follow-up

cone-beam computed tomography did not reveal any signs of osteoporosis progression, decreased bone density, or bone resorption following orthodontic treatment (Fig. 3).

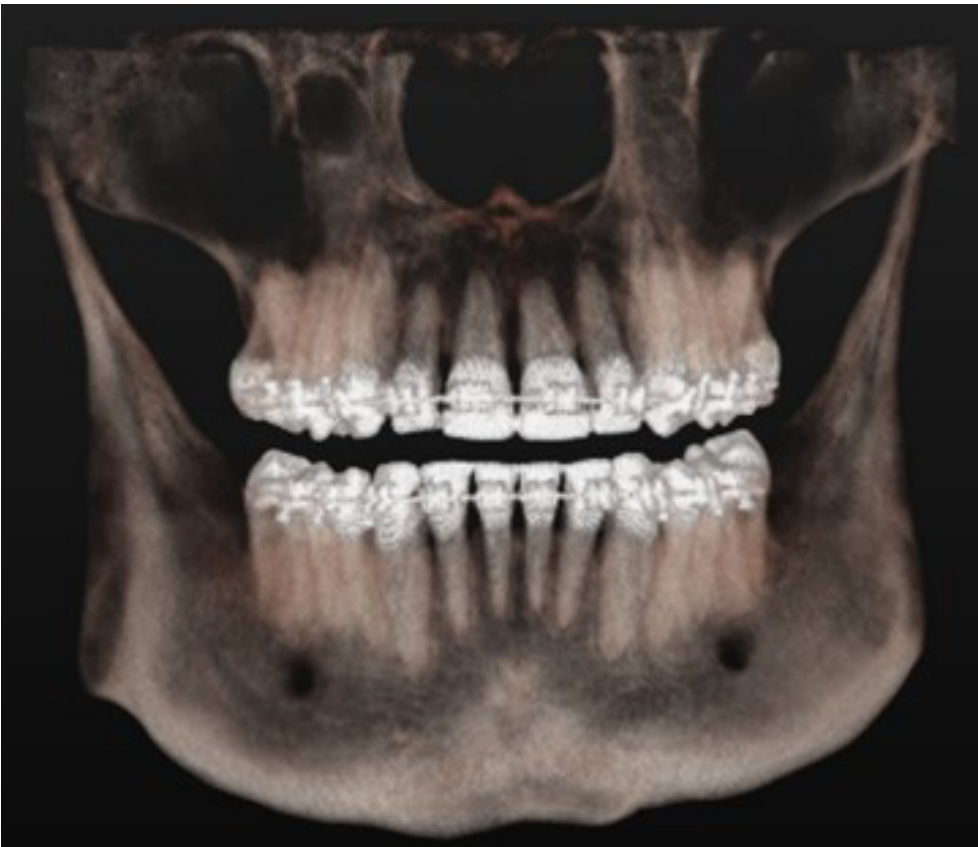

Fig. 3. CBCT of a patient with JIA and malocclusion.

Table 1. Periodontal and oral hygiene status of patients with JIA before and after orthodontic treatment

Indicators	M±m		p
	Before treatment (n=11)	After treatment (n=11)	
Russell's Periodontal Index (PI)	5,63±0,33	2.95±0.36	<0,05
Greene-Vermillion Simplified Oral Hygiene Index (OHI-S)	2.98±0,26	0.49±0.16	<0,05

The analysis of periodontal and oral hygiene status in patients after using a medicinal mixture of silica gel and bacteria *B. subtilis* B-7812(AX20) and *B. licheniformis* IMB B-7811(EA22) has showed a pronounced reduction in the manifestations of periodontal inflammation and an improvement in the hygienic condition of the oral cavity. The mean value of PI decreased significantly from 5.63±0.33 before the probiotic usage to 2.95±0.36 after and the mean value of OHI-S decreased from 2.98±0,26 to 0.49±0.16 after the treatment (Table 1).

DISCUSSION

The results of the study show that significant levels of caries, periodontal lesions were revealed in young patients with juvenile idiopathic arthritis. Almost all examined patients had certain signs of occlusal disorders and TMJ dysfunctions. That’s why such patients may need a comprehensive complex of dental prophylaxis and rehabilitation measures in order to keep their oral

health and prevent the development or progressing of occlusal and TMJ disorders. This emphasizes the importance of the development of interdisciplinary protocols for the management of patients with Juvenile Idiopathic Arthritis and malocclusions which can be complicated by inflammatory periodontal diseases. The rehabilitation of such patients should extend beyond orthodontic treatment and be founded on an interdisciplinary approach, involving pediatric rheumatologists, maxillofacial surgeons, orthodontists, radiologists, pediatric dentists, prosthodontists, physiotherapists, and orofacial pain specialists [7, 8].

The goals of TMJ arthritis management are timely diagnosis, reduction of TMJ inflammation, decreasing orofacial symptoms, optimization of orofacial function, normalization of dentofacial growth and correction of dentofacial deformities. Occlusal splints are commonly used to help support and balance both TMJs and to prevent further pain and discomfort to the TMJ complex during orthodontic treatment. Occlusal splints are safe,

low cost and allow the patient to have even contacts when the teeth occlude in all ranges of motion including biting and side to side jaw movements, which can result in decreased TMJ arthritis-related manifestations and improved mandibular function. Proposed mechanisms for these outcomes include the repositioning of the condylar head in the TMJ, reduction of excessive pressure on the joint surfaces, a temporary decrease in masticatory muscle activity, a reduction in bruxism, achieving balanced occlusion and the potential placebo effect [8-10].

Modern scientific studies show that there is evidence that periodontal disease and rheumatoid arthritis are linked by common immunoinflammatory reactions of imbalance in the pathogenetic basis of both diseases, have similarity of allelic genes and a common imbalance of the state of the cytokine network. There is a hypothesis according to which the mechanism of bone resorption in periodontitis also underlies the progression of joint lesion in patients with rheumatoid arthritis [11].

Our own observations convincingly indicate a significantly higher proportion of patients with generalized periodontitis and moderate destructive changes and inflammatory signs in the periodontium, which may indicate the onset of rapidly progressive periodontitis in young patients with JIA and serve as an additional motivating factor for the prevention and treatment of the primary disease.

Pronounced antimicrobial properties of probiotic strains make it possible to consider the possibility of using drugs based on them as an alternative to antibiotics, which is especially relevant in the era of the rapid spread of resistant forms of pathogenic microorganisms and the decrease in the effectiveness of a number of antimicrobial agents [12]. As a result of numerous pre-clinical and clinical studies of *Bacillus subtilis* and *Bacillus licheniformis* strains, good perspectives of these microorganism's usage for the treatment and prevention of periodontal tissue diseases were established [12]. Previously conducted microbiological studies have shown that the proposed mixture of silica gel and bacteria strains of *B.*

subtilis and *B. licheniformis* has a pronounced antimicrobial activity both on the test strains of microorganisms and on the mixed microbial flora of the periodontal pockets of patients with generalized periodontitis [14]. Our study has also shown that probiotics usage has a pronounced therapeutic effect on periodontal tissues and significantly improves the local hygienic status of patients with chronic periodontitis who undergo orthodontic correction with fixed appliances, therefore it can be recommended for use in order to reduce the risks of developing inflammatory complications during the complex treatment of such patients.







By addressing the specific challenges caused by JIA such as TMJ dysfunction, bone health, medication effects, and psychosocial factors dentists can help manage the complexities of treatment while improving the functional and aesthetic outcomes for the patient. Orthodontic treatment in young patients with juvenile idiopathic arthritis requires careful planning, individualized strategies, and a multidisciplinary approach. Orthodontists should work closely with the patient's rheumatologist to ensure that JIA is under control during orthodontic treatment. Medication adjustments or changes in disease activity can impact the treatment plan, so close coordination is necessary. Regular monitoring, ongoing collaboration with other healthcare professionals, and a focus on both the patient's oral health and overall well-being are key to successful orthodontic management.

CONCLUSIONS

Our study showed that the proposed algorithm of complex rehabilitation of patients with Juvenile Idiopathic Arthritis including implementation proper occlusal analysis and adjustment and probiotics usage during orthodontic treatment of the patients with Juvenile Idiopathic Arthritis within the framework of a personalized approach during all the stages of their rehabilitation ensures minimization of risks and is the key to achieving optimal results.

REFERENCES

1. Kovalenko VM, Omelchenko LI, Yaremenko OB et al. Spadkoiemnist ta efektyvnist terapii yuvenilnoho idiopatichnoho artrytu: napriamky personifikovanoi terapii [Heredity and efficacy of juvenile idiopathic arthritis therapy: directions of personalized therapy]. *Ukrainskyi revmatologichnyi zhurnal*. 2016;2:9-16. (Ukrainian)
2. Boiko Yale. Yuvenilnyi idiopatichnyi artryt: pohliad eksperta na problem [Juvenile idiopathic arthritis: an expert's view on the problem]. <https://health-ua.com/article/62883-yuvenilnij-dopatichnij-artrit-poglyad-eksperta-naproblemu> [Accessed 14 February 2025] (Ukrainian)
3. Carrasco R. Juvenile idiopathic arthritis overview and involvement of the temporomandibular joint: prevalence, systemic therapy. *Oral Maxillofac Surg Clin North Am*. 2015;27(1):1-10. doi: 10.1016/j.coms.2014.09.001. DOI [10.1016/j.coms.2014.09.001](#)
4. Twilt M, Schulten AJ, Nicolaas P et al. Facioskeletal changes in children with juvenile idiopathic arthritis. *Ann Rheum Dis*. 2006;65(6):823-5. doi: 10.1136/ard.2005.042671. DOI [10.1136/ard.2005.042671](#)

5. Caldas W, Conti AC, Janson G, Conti PC. Occlusal changes secondary to temporomandibular joint conditions: a critical review and implications for clinical practice. *J Appl Oral Sci.* 2016;24(4):411–419. doi:10.1590/1678-775720150295. DOI 
6. Symonenko RV, Etnis LO. Suchasni metody diagnostyky zahvoruvan tkanyn parodonta v kontseptsii systemnogo pidhodu likuvannia (Ogliad literatury. Chastyna 2) [Modern methods of diagnosing periodontal tissue diseases in the concept of a systemic treatment approach (Literature review. Part 2)]. *Suchasna stomatolohiya.* 2024;3:24–30. (Ukrainian)
7. Tereshchuk OG, Nespryadko VP, Flis PS et al. Algorithm of complex rehabilitation of patients with iatrogenic occlusal disorders combined with vertical malocclusion. *Wiad Lek.* 2021;74(10):2646–2650.
8. Stoll ML, Kau CH, Waite PD, Cron RQ. Temporomandibular joint arthritis in juvenile idiopathic arthritis, now what? *Pediatr Rheumatol Online J.* 2018;16(1):32. doi: 10.1186/s12969-018-0244-y. DOI 
9. Stoustrup P, Kristensen KD, K  seler A et al. Management of temporomandibular joint arthritis-related orofacial symptoms in juvenile idiopathic arthritis by the use of a stabilization splint. *Scand J Rheumatol.* 2014;43(2):137–45. doi: 10.3109/03009742.2013.830146. DOI 
10. Stoustrup P, Pedersen TK, N  rholm SE et al. Interdisciplinary Management of Dentofacial Deformity in Juvenile Idiopathic Arthritis. *Oral Maxillofac Surg Clin North Am.* 2020;32(1):117–34. doi: 10.1016/j.coms.2019.09.002. DOI 
11. Nazir MA. Prevalence of periodontal disease, its association with systemic diseases and prevention. *Int J Health Sci (Qassim).* 2017;11(2):72–80.
12. Tay Ng E, Boey JRH, Laine SK et al. Antibiotic resistance in the microbiota of periodontitis patients: an update of current findings. *Crit Rev Microbiol.* 2024;50(3):329–340. doi: 10.1080/1040841X.2023.2197481. DOI 
13. Tsubura S, Mizunuma H, Ishikawa S et al. The effect of *Bacillus subtilis* mouth rinsing in patients with periodontitis. *Eur J Clin Microbiol Infect Dis.* 2009;28(11):1353–6. doi: 10.1007/s10096-009-0790-9. DOI 
14. Symonenko RV. Analiz klinichnoi efektyvnosti probiotyky z rodu *Bacillus* pid chas ortodontychnoi korektsii u patsientiv z khronichnym parodontytom dlia znyzhennia ryzykyv uskladnen [Analysis of the Clinical Efficacy of Probiotics from the Genus *Bacillus* During Orthodontic Correction in Patients with Chronic Periodontitis to Reduce the Risk of Complications]. *Suchasna stomatolohiya.* 2024;6:87–91. (Ukrainian)

The article was written as part of research work entitled “Interdisciplinary approach in the prevention, treatment and rehabilitation of patients with periodontal diseases and functional occlusion disorders” (State Registration No. 0123U105134).

CONFLICT OF INTEREST





The Authors declare no conflict of interest







CORRESPONDING AUTHOR




Renata V. Symonenko



Bogomolets National Medical University
1, Zoologichna Str., 03057 Kyiv, Ukraine
e-mail: renataunting@gmail.com



ORCID AND CONTRIBUTIONSHIP



Renata V. Symonenko: 0000-0003-4618-6229      



Leonid O. Etnis: 0000-0002-9409-0910      

Zinaida Y. Zhehulovych: 0000-0002-9996-2060   

Vitalii V. Parii: 0009-0005-2207-5307  

Olena O. Astapenko: 0000-0002-2168-9439  

Daryna I. Bohatyrova: 0000-0003-3779-4097  

Iryna M. Fedianovych: 0000-0002-7997-5411  

 – Work concept and design,  – Data collection and analysis,  – Responsibility for statistical analysis,  – Writing the article,  – Critical review,  – Final approval of the article

RECEIVED: 14.12.2024

ACCEPTED: 30.03.2025

