

A case of duodenal bulb ulcer formation in a soldier of the ukrainian armed forces during ammunition loading

Anatoly A. Avramenko, Anna K. Magdenko

PYLYP ORLYK INTERNATIONAL CLASSICAL UNIVERSITY, MYKOLAIV, UKRAINE

ABSTRACT

Aim: Conduct an analysis and provide a pathophysiological justification for the case of the formation of an ulcer of the duodenal bulb in a 27-year-old soldier of the Armed Forces of Ukraine.

Materials and Methods: After collecting the anamnesis, the patient underwent a comprehensive examination, which included step-by-step pH-metry, esophagogastroduodenoscopy, testing for *Helicobacter pylori* infection (HP) (urease test and microscopic examination of stained smears-prints) in 4 topographic zones of the stomach, and histological examination of the gastric mucosa in the same zones.

Results: When collecting a family history, it was found that relatives on one male line - father and grandfather - suffered from ulcer disease. It was established that on the eve of an exacerbation, which lasted 3 weeks, the soldier helped load a car, repeatedly lifting boxes with ammunition up to 20 kg to a height of 1.5 m. During pH-metry it was found that the acidity level of gastric juice corresponded to the basal normacidity of total. During esophagogastroduodenoscopy the following diagnosis was made: "Ulcer of the duodenal bulb in the active stage (in the middle third, along the back wall, 1.5 x 0.8 cm, the ulcer defect is covered with gray fibrin). Erythematous duodenogastropathy. Indirect signs of pancreatopathy." The presence of chronic gastritis in the active stage in the patient was confirmed by the results of histological examination of the gastric mucosa. The type of gastritis (non-atrophic) was confirmed by testing for HP infection, which revealed a high concentration of the active form of bacteria - (++++) in all 4 topographic zones of the stomach.

Conclusions: Stress associated with participation in military operations led to the active reproduction of *Helicobacter pylori* infection and, accordingly, an increase in "residual" ammonia in the stomach cavity. Heavy physical exertion, which was accompanied by a sharp contraction of the muscles of the anterior abdominal wall, created a "bellows" effect, which concentrated the "residual" ammonia in the cavity of the duodenal bulb and led to the formation of an ulcer.

KEY WORDS: *Helicobacter pylori*, «bellows» effect

Wiad Lek. 2025;78(7):1298-1301. doi: 10.36740/WLek/208989 DOI

INTRODUCTION

The basis for the formation of ulcers of the duodenal bulb is the presence of chronic non-atrophic gastritis in patients, the etiological factor of which is *Helicobacter pylori* infection (HP) [1-7]. The formation of ulcers of the duodenal bulb occurs under different circumstances, at any age, regardless of gender, in any profession, but fits into a single mechanism, which is revealed in the new theory of ulcer formation (the theory of "caustic alkaline spit") [8-11]. One of the important roles in the mechanism of ulcerative defect formation is played by physical activity, which is accompanied by a sharp rhythmic contraction of the muscles of the anterior abdominal wall [8-11]. From this point of view, the case of rapid formation of an ulcer of the duodenal bulb after physical activity in a soldier of the Armed Forces of Ukraine, associated with his participation in military operations, is interesting.

AIM

Conduct an analysis and provide a pathophysiological justification for the case of the formation of an ulcer of the duodenal bulb in a 27-year-old soldier of the Armed Forces of Ukraine.

MATERIALS AND METHODS

Patient S., 27 years old, came to a gastroenterologist at the Center for Progressive Medicine and Rehabilitation "Rea + Med" (Nikolaev) on 10.02.23 for examination and treatment.

The patient underwent a comprehensive examination (No. 7688 dated 10.02.23). To determine the basal acidity level, step-by-step pH-metry was used according to the method of V.N. Chernobrov. To determine the condition of the upper gastrointestinal tract (esophagus, stomach, duodenum), the patient underwent esoph-

Table 1. Basal acidity level of gastric juice

Acidity level	Parameters of levels (pH)	Number of values identified during the study (40 measurement points)	%
Severe hyperacidity	0,90 – 1,29	0	0
Moderate hyperacidity	1,30 – 1,59	0	0
Normacidity	1,60 – 2,29	40	100
Moderate hypoacidity	2,30 – 3,59	0	0
Severe hypoacidity	3,60 – 6,99	0	0
Anacidity	7,00-7,50	0	0

Table 2. Test results of gastric mucosa on HP infection for topographical zones

Antrum				Fundus of stomach			
Large curvature		Small curvature		Large curvature		Small curvature	
Microscopic analysis	Urease test	Microscopic analysis	Urease test	Microscopic analysis	Urease test	Microscopic analysis	Urease test
(+++) Active form, mitosis	25 min	(+++) Active form, mitosis	25 min	(+++) Active form, mitosis	20 min	(+++) Active form, mitosis	20 min

agogastrroduodenoscopy (EGDS) under local anesthesia according to the generally accepted method. The study for *Helicobacter pylori* infection (HP) (the presence of bacteria, the degree of contamination of the gastric mucosa, the presence of intracellular “depots”) was carried out using two methods - a urease test and microscopy of stained smears - prints in comparison, for which biopsies of the gastric mucosa were used, taken from 4 topographic zones (the middle third of the antral section and the body of the stomach along the greater and lesser curvature). Each biopsy was divided into two parts: one half was used for the urease test, the second for making a smear-print, which increased the reliability of the research and made it possible to identify intracellular “depots” of HP infection. To conduct histological studies to study the condition of the gastric mucosa, biopsy material of the mucosa taken from the same 4 topographic zones of the stomach was used [8, 10, 12, 13].

The study was conducted in accordance with the main bioethical provisions of the Helsinki Declaration of the World Medical Association on Ethical Principles for Medical Research Involving Human Subjects (1964-2013) and the order of the Ministry of Health of Ukraine No. 690 of September 23, 2009, which is confirmed by the conclusions of the meeting of the Ethics Commission of the Pylyp Orlyk International Classical University, Mykolaiv No. 2 of February 14, 2025 [14, 15].

RESULTS

During the survey, it was found that the patient complained of periodic dull and sharp pains in the epigastrium, a feeling of heaviness after eating, heartburn, sleep disturbances and loss of appetite. During the survey, it was found that the exacerbation lasted for 3 weeks. On the eve of the exacerbation, the patient (a serviceman of the Armed Forces of Ukraine) helped load a car, repeatedly lifting boxes of ammunition weighing up to 20 kg to a height of 1.5 m.

When collecting a family history, it was found that the ulcerative process was traced in the patient's family along the male line: the father (50 years old) suffered from a duodenal ulcer at the age of 29, and the grandfather (74 years old) suffered from a gastric ulcer at the age of 54.

The data from the study of basal acidity of gastric juice are presented in table 1. When analyzing the results obtained, it was established that the patient's basal acidity level corresponded to total normacidity.

During the EGDS, the following diagnosis was made: “Ulcer of the duodenal bulb in the active stage (in the middle third, along the posterior wall, 1.5 x 0.8 cm, the ulcer defect is covered with gray fibrin). Erythematous duodenogastropathy. Indirect signs of pancreatopathy.”

The presence of a chronic inflammatory process in the gastric mucosa and its activity was confirmed by histological studies of biopsies of the gastric mucosa

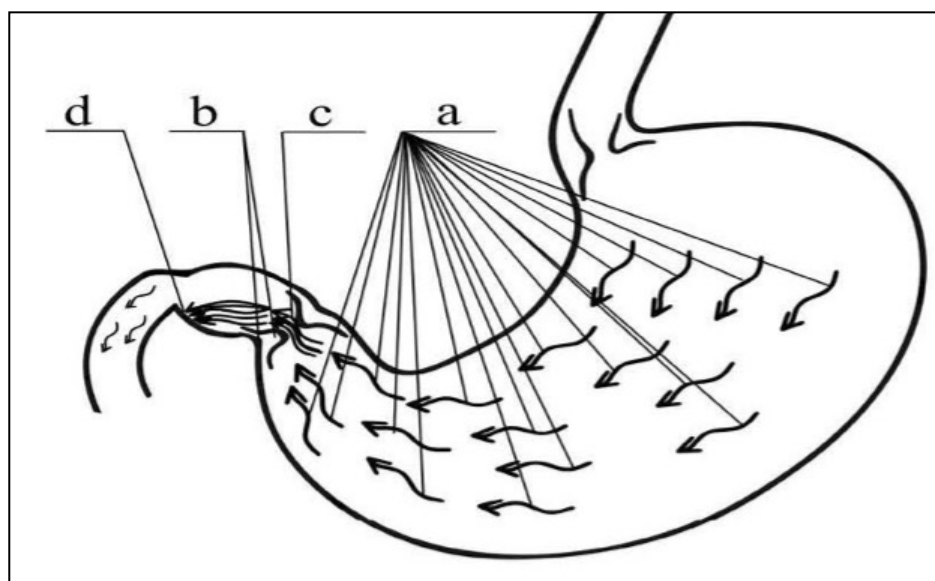


Fig. 1. The mechanism of formation of ulcerative lesions of the duodenal bulb in patients with chronic helicobacteriosis: a) flow direction "residual" ammonia in the gastric cavity; b) the pyloric sphincter in half-bent state; c) the place of the maximum concentration of "residual" ammonia (pyloric canal) in the form of sustainable dense flow; d) the place of ulcerative lesions of the duodenal bulb tissues (any bulb department duodenal ulcer)

taken from 4 topographic zones: in the middle third of the antral part of the stomach along the lesser curvature, a picture of chronic active gastritis with process activity of (+++) was revealed; in the middle third of the antral part of the stomach along the greater curvature, a picture of chronic active gastritis with process activity of (+++) was revealed; in the middle third of the body of the stomach along the lesser curvature, a picture of chronic active gastritis with process activity of (++) was revealed; in the middle third of the body of the stomach along the greater curvature, a picture of chronic active gastritis with process activity of (+++) was revealed.

The type of gastritis (non-atrophic) was confirmed by examining the gastric mucosa for HP infection in 4 topographic zones: a high degree of mucosal contamination with active forms of bacteria was detected in all zones – (+++). The results of these studies are presented in table 2.

DISCUSSION

This case can be explained from the perspective of knowledge about the vital activity of HP infection, the influence of stress on the development of chronic *Helicobacter pylori* infection, and a new theory of ulcer formation – the theory of "caustic alkaline spit" [8-10].

HP infection produces the enzyme urease to protect itself from hydrochloric acid, which breaks down food urea into ammonia. The resulting ammonia, when combined with water, forms an alkali - ammonium hydroxide, which neutralizes the hydrochloric acid around the bacteria. However, not all of the resulting ammonia immediately forms ammonium hydroxide: some of it accumulates in the stomach cavity ("residual" ammonia

(RA)). During prolonged stress, which is participation in military operations, there is a deterioration in immune protection and a decrease in the acidity of gastric juice, which leads to rapid proliferation of HP infection and an increase in its mass on the gastric mucosa, which is confirmed by our studies. An increase in the mass of bacteria also leads to an increase in the volume of OA [8-10].

According to the new theory, with sharp rhythmic physical exertion, when sharp tension of the muscles of the anterior abdominal wall leads to a sharp rhythmic increase in intra-abdominal pressure and, as a consequence of this, according to Pascal's law, to a sharp rhythmic increase in intra-gastric pressure, the "bellows" effect occurs, when OA is concentrated in a narrow place - in the pyloric canal and the bulb of the duodenum, where the humidity is 98%. This leads to the local formation of ammonium hydroxide at a high concentration on the mucous membrane of the duodenal bulb, which leads to damage to the mucous membrane of the duodenal bulb and the formation of an ulcer defect [8-11]. Fig. 1 shows a graphical representation of this process [8].

CONCLUSIONS

1. Stress associated with participation in military operations led to the active reproduction of *Helicobacter pylori* infection and, accordingly, an increase in "residual" ammonia in the stomach cavity.
2. Heavy physical exertion, which was accompanied by a sharp contraction of the muscles of the anterior abdominal wall, created a "bellows" effect, which concentrated the "residual" ammonia in the cavity of the duodenal bulb and led to the formation of an ulcer.

REFERENCES

1. Cherniavskiy VV, Pavlovskiy LL, Reshotko DO. Dosvid zastosuvannya riznykh skhem eradykatsiinoi terapii infektsii *Helicobacter pylori* ta yikh efektyvnist v Ukraini [Experience in the use of various regimens for eradication therapy of *Helicobacter pylori* infection and their effectiveness in Ukraine]. *Gastroenterologia*. 2024;1(58):1-5. doi: 10.22141/2308-2097.58.1.2024.579. (Ukrainian) [DOI](#)
2. Bordin DS, Voynovan IN, Andreev DN et al. Current *Helicobacter pylori* Diagnostics. *Diagnostics* (Basel). 2021;11(8):1458. doi: 10.3390/diagnostics11081458. [DOI](#)
3. Elbehiry A, Marzouk E, Aldubaib M et al. *Helicobacter pylori* Infection: Current Status and Future Prospectson Diagnostic, Therapeutic and Control Challenges. *Antibiotics* (Basel). 2023;12(2):191. doi: 10.3390/antibiotics12020191. [DOI](#)
4. Feldman M, Friedman LS, Brandt LJ et al. *Sleisenger and Fordtran's Gastrointestinal and Liver Disease: Pathophysiology, Diagnosis, Management*. 11th ed. Elsevier. 2020, p.2488.
5. Malfertheiner P, Megraud F, Rokkas T et al. Management of *Helicobacter pylori* infection: the Maastricht VI/Florence consensus report. *Gut*. 2022;71(9):1724–1762. doi: 10.1136/gutjnl-2022-327745. [DOI](#)
6. Osyodlo GV, Kotyk YY, Kalashnikov MA et al. Prevalence, clinical course and treatment of chronic gastritis at the present stage. *Gastroenterology*. 2021;55(2):74-80. doi: 10.22141/2308-2097.55.2.2021.233627. [DOI](#)
7. Venkata Ramakrishna T, Manoj K. Afr. J. Biomed. Res. 2024;27:2987-2990. doi: 10.53555/AJBR.v27i15.1962. [DOI](#)
8. Avramenko AA. The case of formation of <kissing> ulcers of duodenal bulb of the patient with chronic nonatrophic gastritis on the background of the eating of a vegetable salad and physical exertion. *Wiad Lek*. 2019;72(5):946-949.
9. Avramenko AO. Patent 93273 Ukraine, MPK G01N 33/48 (2006.01) Sposib testuvannya gelikobakternoyi infektsii u khvorikh na khronichniy gelikobakterioz [Method of testing helicobacteric infection in patients with chronic helicobacteriosis]. № u201403956; zayavl. 14.04.2014; opubl.25.09.2014. Byul. №18. – 3. (Ukrainian)
10. Kimakovich VY, Nikishaev VI et al. Yendoskopiya travnogo kanalu. Norma, patologiya, suchasni klasifikatsiyi [Endoscopy of the digestive canal. Norm, pathology, modern classifications]. Lviv: Vidavnistvo Meditsina Svitu. 2008, p.208 s. (Ukrainian)
11. Avramenko AA, Gozhenko AI, Godyk VS et al. Yazvennaya bolezni (ocherki klinicheskoy patofiziologii) [Peptic ulcer disease (essays on clinical pathophysiology)]. Odessa : OOO «RA «ART-V». 2008, p.304. (Russian)

The work is a fragment of research work « Improving the prevention and treatment of major environmentally dependent and occupationally related diseases based on studying the features of their etiology and pathogenesis », the state registration number 0116U008822.

CONFLICT OF INTEREST

The Authors declare no conflict of interest

CORRESPONDING AUTHOR

Anatoly A. Avramenko

Pylyp Orlyk International Classical University,

2 Kotelna St, 254000 Mykolaiv, Ukraine

e-mail: aaahelic@gmail.com

ORCID AND CONTRIBUTIONSHIP

Anatoly A. Avramenko: 0000-0002-9652-089X [A](#) [D](#) [F](#)

Anna K. Magdenko: 0009-0006-0880-3125 [B](#) [E](#)

[A](#) – Work concept and design, [B](#) – Data collection and analysis, [C](#) – Responsibility for statistical analysis, [D](#) – Writing the article, [E](#) – Critical review, [F](#) – Final approval of the article

RECEIVED: 08.02.2025

ACCEPTED: 29.06.2025

