

Study of changes in the length of the anterior talo-fibular ligament in patients with symptoms of the ankle-foot joint instability

Yurii Hrubar¹, Iryna Ya. Hrubar², Markiiian Yu. Hrubar³, Yuliana Yu. Hrubar³, Nadiia M. Hrabyk², Olha V. Hulka²

¹ HORBACHEVSKY TERNOPIL NATIONAL MEDICAL UNIVERSITY, TERNOPIL, UKRAINE

² TERNOPIL VOLODYMYR HNATIUK NATIONAL PEDAGOGICAL UNIVERSITY, TERNOPIL, UKRAINE

³ TERNOPIL REGIONAL CLINICAL HOSPITAL, TERNOPIL, UKRAINE

ABSTRACT

Aim: To study changes in the length of the anterior talo-fibular ligament (ATFL) by measuring it before and during manual inversion loading in the presence of symptoms of chronic ankle-foot joint instability.

Materials and Methods: The study was conducted in patients of two age groups: 20-29 and 30-39 years. The length of the ligament was determined sonographically in the neutral position and in the position of maximum inversion.

Results: According to the results of the study, the average length of the uninjured ATFL in men in the neutral position was 19.08 ± 0.3 mm. With inversion loading, the length of the ligament increased to 19.65 ± 0.3 mm. In women, the average length of the uninjured ATFL in the neutral position was 16.92 ± 0.2 mm, with inversion loading - 17.37 ± 0.2 mm. With joint instability, the average length of the ATFL on the side of the injury in the neutral position was 19.13 ± 0.36 mm, with inversion loading - 20.35 ± 0.44 mm. The statistical difference in the length of the ATFL between the neutral position and inversion loading on the side of the injury was 1.25 ± 0.04 mm ($p < 0.001$).

Conclusions: The results of our study show that sonography with inversion loading is a highly sensitive, specific, and accurate imaging method that can be used to diagnose chronic ankle-foot joint instability.

KEY WORDS: sonography, ankle-foot joint instability, anterior talo-fibular ligament, inversion load test

Wiad Lek. 2026;79(2):281-288. doi: 10.36740/WLek/214411 DOI

INTRODUCTION

Acute ankle-foot joint sprains are one of the most common musculoskeletal injuries. This type of injury is particularly common among physically active young people, both in everyday life and in sports [1]. 85% of ankle-foot joint sprains involve the lateral collateral ligament complex. More than 65% of cases involve isolated anterior talo-fibular ligament injuries. Sudden inversion and internal rotation, combined with plantar flexion, place significant stress on the anterior talo-fibular ligament, leading to its rupture [2]. In 20% of cases, this type of injury requires emergency medical attention, but up to 64% of injured individuals do not seek medical attention at all [3]. Recent studies have shown that up to 70% of individuals who sustain an acute lateral ankle-foot joint sprain may develop symptoms of chronic ankle instability (CAI) within a short period of time after the initial injury [4].

To prevent these complications, high-quality diagnostics and subsequent selection of treatment tactics, which should be started quickly and in full, remain important. To date, limited evidence has been shown for many widely used special orthopedic tests for ankle-foot joint injuries [5]. Among non-invasive instrumental diagnostic methods, sonography, stress radiography, and magnetic resonance imaging are most often used. The results of stress radiographs are questioned because they are seriously affected by the radiography technique, the magnitude of the force applied during the examination, and the patient's reaction to the examination [6]. Magnetic resonance imaging is the most accurate diagnostic method for assessing ankle-foot joint injuries, given its high resolution and accuracy. However, MRI does not show the dynamic function of the ligaments, and its use in acute trauma is considered inappropriate [7].



Fig. 1. Ankle-foot joint ultrasound device
Picture taken by the authors

Today, sonography is becoming increasingly important in assessing the condition of the ligamentous apparatus of the joints, and the sensitivity of ultrasound in detecting injuries to the anterior calcaneal-fibular ligament is up to 93% [8]. Dynamic examination in the form of stress tests makes it possible to sonographically assess the degree of joint instability, simultaneously determine the condition of the ligaments of the contralateral joint and conduct a comparative analysis [9]. Thus, in case of ankle-foot joint damage, ATFL ultrasound assessment is a highly reliable procedure due to the practicality of both dynamic and static assessment of the ligament condition [10].

AIM

Study of changes in the length of the anterior talo-fibular ligament by measuring it before and during manual inversion loading in age groups most frequently exposed to its damage in the presence of symptoms of chronic ankle-foot joint instability.

MATERIALS AND METHODS

SELECTION OF PARTICIPANTS

The control group (CG) consisted of students of Ternopil National Medical University and Ternopil National Ped-

agogical University, who voluntarily participated in the study. The average length of the anterior talo-fibular ligament on both limbs in a neutral position and with inversion loading was studied. The average value of the length of the anterior talo-fibular ligament of the right and left ankle-foot joint in each position was recorded in the protocol. The average age was 22.63 ± 0.11 years in men and 22.54 ± 0.12 years in women. The experimental group (EG) initially included 59 patients with signs of chronic ankle-foot joint instability, who underwent examination in the clinic from 2019 to 2024. Of these, 37 (62.72%) were men, 22 (39.28%) were women; the average age was 32.3 ± 2.8 years. At the final stage of the study, 49 patients remained in the experimental group for one reason or another. In the process of studying the stability of the ankle-foot joint in the study groups, we used standard inclusion and exclusion criteria approved by the International Ankle Consortium.

RESEARCH METHODOLOGY

Sonography of the ligament was performed using a Siemens Acuson S2000 ultrasound console with a high-frequency broadband linear transducer with an operating frequency of 7–12 MHz, using standard acoustic gel.

Patient positioning. Measurements of the anterior talo-fibular ligament length in both groups were

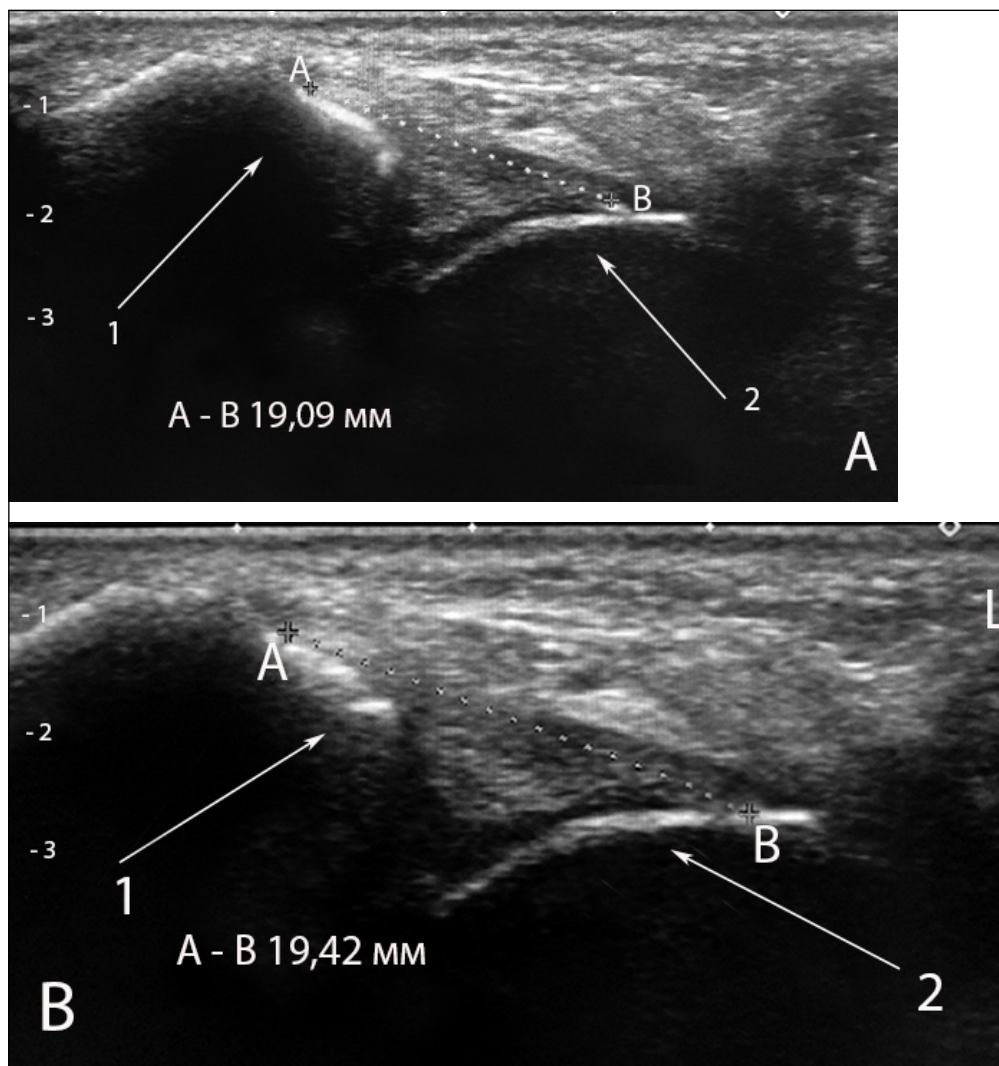


Fig. 2. Length measurement of the anterior talo-fibular ligament (ATFL) in a neutral position during sonography in a control patient. A. Dimensions of the anterior talo-fibular ligament in a neutral position in a patient of the control group (A-B measurement points of the anterior talo-fibular ligament. 1 - fibula; 2 - talus). B. Dimensions of the anterior talo-fibular ligament during inversion loading in a patient of the control group (A-B measurement points of the anterior talo-fibular ligament. 1 - fibula; 2 - talus)

Picture taken by the authors

performed in two positions (neutral and maximum inversion), three times per position in each patient, to obtain the average ligament length.

In the first position, the subjects held the examined limb on the ankle-foot joint ultrasound device (Fig. 1) in a position of flexion in the knee joint at an angle of 45°, and the ankle-foot joint area hung freely in a position of plantar flexion to an angle of 20°. This position was defined as the neutral resting position and the baseline value for each subsequent measurement of the anterior talo-fibular ligament length [11].

During the sonographic examination, the distance from the anterolateral edge of the lateral bone, corresponding to the origin of the anterior talo-fibular ligament, to the anterolateral angle of the lateral surface of the talus, corresponding to the anatomical site of its fixation, was measured. The length of the ligament was measured on a longitudinal ultrasound image using a Preset of the sonographic apparatus, which allowed measurements to be made with an accuracy of two decimal places. (Fig. 2. A, B).

In the second position (maximum inversion loading position): the limb was in a neutral position, the researcher performed maximum inversion at the ankle-foot joint while holding the foot in a position of plantar flexion. The length of the anterior talo-fibular ligament in the inversion loading position was determined on the longitudinal ultrasound image as a straight line between the above-described bony landmarks (Fig. 3. A, B).

STATISTICAL ANALYSIS

Statistical analysis was performed using Statistica 8.0 software. Results were presented as average values with 95% confidence interval. The Shapiro-Wilk test was used to confirm whether the data were normally distributed. When the data showed a normal distribution, the Student's t-test was performed to compare continuous data. Otherwise, the Mann-Whitney U-test was performed. The chi-square test or Fisher's exact test was used to compare categorical data. The Wilcoxon signed-rank test was performed to compare the ultrasound results for the right and left ankles.

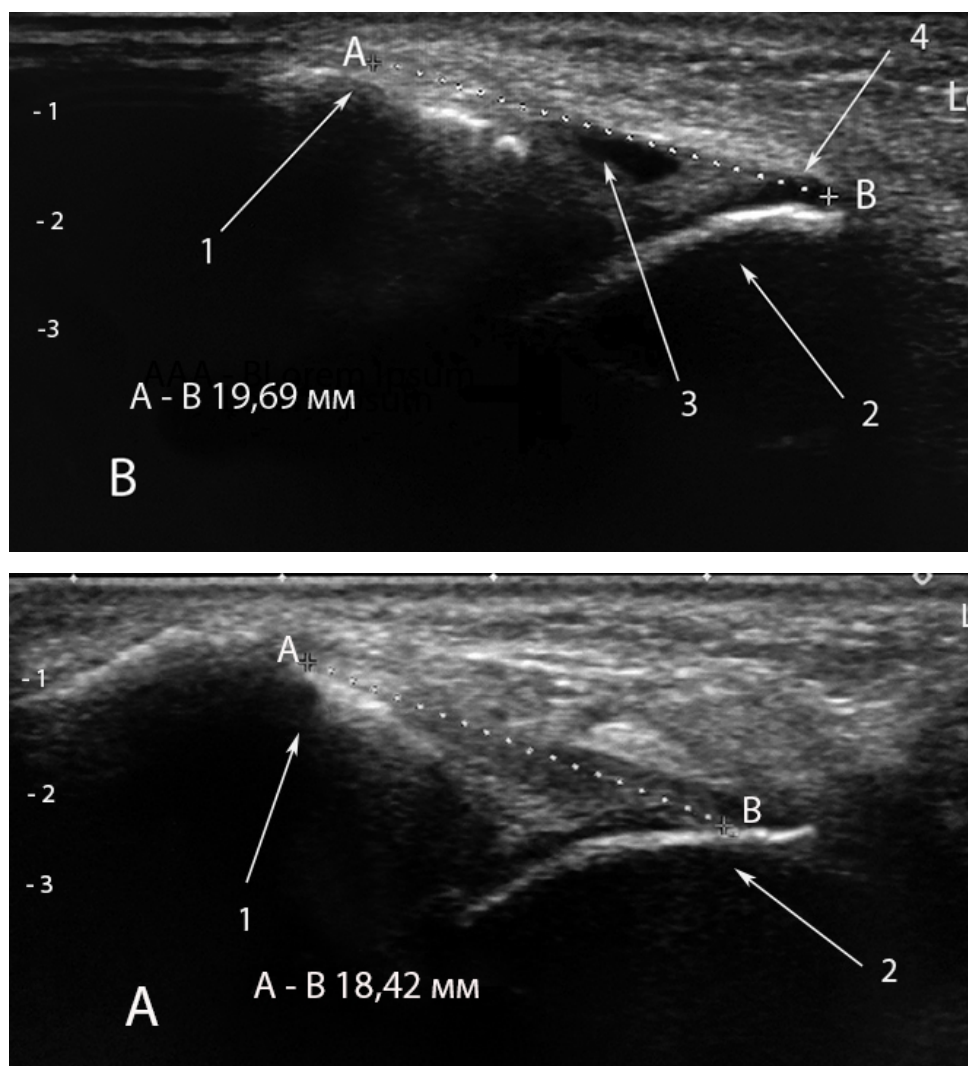


Fig. 3. Anterior talo-fibular ligament of the experimental group patient with chronic ankle-foot joint instability during sonography. A. Dimensions of the anterior talo-fibular ligament in a neutral position in a patient of the experimental group with chronic ankle-foot joint instability (A-B measurement points of the anterior talo-fibular ligament. 1 - fibula; 2 - talus). B. Dimensions of the anterior talo-fibular ligament at maximum inversion loading in a patient of the experimental group with chronic instability of the ankle-foot joint (A-B measurement points of the anterior talo-fibular ligament. 1 - fibula; 2 - talus; 3 - free fluid in the joint cavity; 4 - place of detachment of the anterior talo-fibular ligament from the talus)

Picture taken by the authors

ETHICS

This work complies with the principles of the Declaration of Helsinki.

RESULTS

In the first stage of the research, sonographic measurements of the length of the intact anterior talo-fibular ligament of the control group (age 20-29 years) were compared with the length of the ligament on the contralateral side of the experimental group (age 30-39 years) in a neutral position and with inversion loading in order to determine the effect of the patients' age on changes in its length.

In men of the control group, the average ATFL length in the neutral position was 19.11 ± 0.32 mm, and with inversion loading - 19.68 ± 0.33 mm ($p < 0.001$). The elongation of the ligament was 0.57 ± 0.01 mm. In men of the experimental group, the average ATFL length in the neutral position was 19.00 ± 0.40 mm, and with inversion loading - 19.61 ± 0.33 mm ($p < 0.001$). The elongation of the ligament was 0.56 ± 0.01 mm. The data obtained

by us indicate that there is no statistically significant difference between male patients of the control and experimental groups in terms of ATFL length in different states ($p > 0.05$) (Table 1).

In women of the control group, the average length of the ATFL in the neutral position was 16.97 ± 0.19 mm, and with inversion loading - 17.42 ± 0.20 mm ($p < 0.001$). The elongation of the ligament was 0.45 ± 0.01 mm. In women of the experimental group, the average length of the ATFL in the neutral position was 16.99 ± 0.22 mm, with inversion loading - 17.45 ± 0.24 mm ($p < 0.001$). The elongation of the ligament was 0.46 ± 0.01 mm.

These data indicate that there is no statistically significant difference between female patients in the control and experimental groups in terms of ATFL length in different states ($p > 0.05$) (Table 1).

In men of the CG and EG, the length of the ATFL in the neutral position and with inversion loading was greater than in women of the same groups at the level of statistical probability ($p < 0.001$). The intraclass correlation coefficients for neutral and tense ligament lengths were 0.85-0.9, indicating good reliability of the study results.

Table 1. Length indicators of the intact ATFL in the neutral and inversion positions in patients of the study groups

| Gender | Men | | | Women | | | |
|---|----------------------------------|-----------------------------------|---------------------|----------------------------------|-----------------------------------|---------------------|---------|
| Group | ATFL length neutral position, mm | ATFL length inversion loading, mm | ATFL elongation, mm | ATFL length neutral position, mm | ATFL length inversion loading, mm | ATFL elongation, mm | P (m/w) |
| CG | 19.11±0.32 | 19.68±0.33 | 0.57±0.01 | 16.97±0.19 | 17.42±0.20 | 0.45±0.01 | <0.001 |
| EG | 19.00±0.40 | 19.61±0.33 | 0.56±0.01 | 16.99±0.22 | 17.45±0.24 | 0.46±0.01 | <0.001 |
| Statistical difference CG/EC | >0.05 | >0.05 | >0.05 | >0.05 | >0.05 | >0.05 | |
| CG statistical difference (neutral position/inversions) | | <0.001 | | | <0.001 | | |
| EG statistical difference (neutral position/inversions) | | <0.001 | | | <0.001 | | |

Source: compiled by the authors of this study

Table 2. Average length of intact ATFL in neutral position and with inversion loading in patients of the study groups

| Position | Average length of the anterior talo-fibular ligament | | |
|-----------------------|--|--------------------|------------------------------|
| | Control group | Experimental group | Statistical difference CG/EG |
| Neutral position, mm | 18.04±0.12 | 17.99±0.18 | p>0.05 |
| Inversion loading, mm | 18.55±0.13 | 18.53±0.13 | p>0.05 |
| Length change, mm | 0.51±0.007 | 0.51±0.006 | p>0.05 |

Source: compiled by the authors of this study

Table 3. Average ATFL length indicators in neutral position and at maximum inversion loading in the experimental group

| Side | Contralateral side | Damaged side | Statistical difference contralateral/injured |
|--|--|--------------|--|
| Position | Average length of the anterior talo-fibular ligament | | |
| Neutral position, mm | 17.99±1.06 | 19.13±0.36 | p<0.001 |
| Inversion loading, mm | 18.53±1.12 | 20.35±0.44 | p<0.001 |
| Length change, mm | 0.51±0.05 | 1.25±0.04 | p<0.001 |
| Statistical difference between the positions | p<0.05 | p<0.001 | |

Source: compiled by the authors of this study

The generalized average length of the ATFL in the control group in the neutral position was 18.04±0.12 mm, and at maximum inversion - 18.55±0.13 mm, the change in length was 0.51±0.007 mm. In the experimental group, these indicators were as follows: in the neutral position, the length of the ligament was 17.99±0.18 mm, with inversion loading - 18.53±0.13 mm, and the elongation was 0.51±0.006 mm. There is no statistical difference between the indicators of the control and experimental groups (p>0.05). This gives us reason to believe that the length of the intact ATFL in the neutral position and with inversion loading in both study groups does not change with age (Table 2).

In the second stage of the study, the length of the anterior talo-fibular ligament on the contralateral side and the side of the injury in the neutral position and at maximum inversion loading was compared in the experimental group (Table 3).

In the experimental group, the average values of the length of the anterior talo-fibular ligament in the neutral position on the contralateral side were 17.99±1.06 mm, and with maximum inversion - 18.53±1.12 mm (p<0.05). The change in the length of the ligament was 0.51±0.05 mm. The average values of the ATFL length in the neutral position on the side of injury were 19.13±0.36 mm, with maximum inversion - 20.35±0.44 mm. The change in its length was 1.25±0.04 mm on average (p<0.001).

DISCUSSION

This article is a continuation of the study of the condition of the lateral ligament complex of the ankle-foot joint when it is damaged in young people, which we have been conducting since 2019.

During physical examination, the standard tests used to detect lateral instability are the front box, talus,

and inversion stress test [12]. According to Beynon A., physical examination is limited by subjectivity and difficulties in recognizing the degree of ligament stability, as well as identifying the specific injured ligament [13]. Dynamic sonography has a high potential for detecting ankle-foot joint ligament instability, but the value parameters of the change in length of the anterior talo-fibular ligament during inversion loading in patients with signs of chronic lateral instability in different age groups have not been fully determined.

Our study methodology meets the current requirements for performing sonographic inversion loading. The internal rotation moment at plantar flexion to an angle of 30° is considered optimal for assessing increased translation of the ankle-foot joint with ATFL insufficiency, when using stress ultrasound examination [14].

The results of our study show that ATFL lengths in both neutral and inversion loading can be effectively measured using manual stress sonography. Thus, the average ATFL length in the neutral position in men of the control and experimental groups is 19.11±0.32 and 19.00±0.40 mm, in women, respectively, 16.97±0.19 - 16.99±0.22 mm. They are in the range of the stated values from 19.2 to 20.31±3.12 mm which were measured in bone-ligamentous preparations of cadaveric ankle-foot joints [15]. By measuring ATFL length on 50 cadaveric joints, Khawaji B. et al. found that ATFL length ranged from 18.81 mm in dorsiflexion to 21.06 mm in plantar flexion [16].

In addition, the average length of the ATFL, both for men and women in our study, is consistent with the figures of Dong Y. et al. who reported that changes in the length of the ATFL in vivo in healthy ankle-foot joints range from 16 mm in the neutral position to 20.8 mm during active plantar flexion of the ankle-foot joint and supination [17].

In MRI examinations, Szaro P. et al. indicate that the length of the ATFL can vary from 13-14 mm to 21-22 mm and the values obtained depend on the methodology of the study and variations in the structure of the ligament bundles [18].

In sonography, the average length of the ATFL of the non-tensioned ligament is 19.50 ± 1.81, and of the tensioned ligament is 21.08 ± 1.98 [19].

We showed a statistically significant difference comparing the changes in ATFL length in asymptomatic subjects 0.51±0.07 mm and patients with anterolateral instability 1.25±0.04 mm ($p<0.001$). The average change in ATFL length between neutral state and inversion loading in the symptomatic group was almost 2.5 times greater compared to asymptomatic patients. In an ultrasound study, Cho J.H. et al found that the ATFL ratio (tension/rest) was 1.3±0.1 mm [20]. Similar results were obtained in the studies of Kamada K et al. [21]. Our results are consistent with the data of Kikumoto T. et al. who concluded that the change in ATFL length during inversion loading with plantar flexion of the foot was statistically significantly greater than in healthy individuals [22].

CONCLUSIONS

During the study, it was found that the length of the intact ATFL in a neutral position and under inversion loading in patients of the studied groups does not change with age.

The average values of the ATFL length in a neutral position on the side of the injury were 19.13±0.36 mm, with maximum inversion - 20.35±0.44 mm. The change in its length was on average 1.25±0.04 mm ($p<0.001$), which may indicate chronic instability of the ankle-foot joint.

Thus, inversion loading sonography is a highly sensitive, specific, and accurate imaging method that can be used to diagnose chronic ankle-foot joint instability.

A potential limitation of this study was that there was some subjective assessment of the ATFL during the sonographic examination. We also did not determine the force applied during inversion loading. Future studies should aim to standardize testing methods and ligament length measurements to provide an objective definition of chronic ankle-foot joint instability.

REFERENCES

1. Miklovic TM, Donovan L, Protzuk OA et al. Acute lateral ankle sprain to chronic ankle instability: a pathway of dysfunction. *Phys Sportsmed.* 2018;46(1):116-122. doi: 10.1080/00913847.2018.1409604. DOI
2. Chen RP, Wang QH, Li MY et al. Progress in diagnosis and treatment of acute injury to the anterior talofibular ligament. *World J Clin Cases.* 2023;11(15):3395-3407. doi: 10.12998/wjcc.v11.i15.3395. DOI
3. Cavazos GJJ, Harkless LB. The epidemiology, evaluation, and assessment of lateral ankle sprains in athletes. *J Sports Med Therapy* 2021;6(2):008-017. doi: 10.29328/journal.jsmt.1001052. DOI
4. Gribble PA, Bleakley CM, Caulfield BM et al. Evidence review for the 2016 International Ankle Consortium consensus statement on the prevalence, impact and long-term consequences of lateral ankle sprains. *Br J Sports Med.* 2016;50(24):1496-1505. doi: 10.12998/wjcc.v11.i15.3395. DOI

5. Larkins LW, Baker RT, Baker JG. Physical Examination of the Ankle: A Review of the Original Orthopedic Special Test Description and Scientific Validity of Common Tests for Ankle Examination. *Arch Rehabil Res Clin Transl.* 2020;2(3):100072. doi: 10.1016/j.arrct.2020.100072. [DOI](#)
6. Cao M, Liu S, Zhang X et al. Imaging diagnosis for anterior talofibular ligament injury: a systemic review with meta-analysis. *Acta Radiol.* 2023;64(2):612-624. doi: 10.1177/02841851221080556. [DOI](#)
7. Park EH, de Cesar Netto C, Fritz J. MRI in Acute Ankle Sprains: Should We Be More Aggressive with Indications? *Foot Ankle Clin.* 2023;28(2):231-264. doi: 10.1016/j.fcl.2023.01.011. [DOI](#)
8. Hosseinian SHS, Aminzadeh B, Rezaeian A et al. Diagnostic Value of Ultrasound in Ankle Sprain. *J Foot Ankle Surg.* 2022;61(2):305-309. doi: 10.1053/j.jfas.2021.08.008. [DOI](#)
9. Park JW, Lee SJ, Choo HJ et al. Ultrasonography of the ankle joint. *Ultrasonography.* 2017;36(4):321-335. doi: 10.14366/usg.17008. [DOI](#)
10. Hattori S, Saggari R, Mullen J et al. Role of Ultrasound in Evaluating Ligament Injuries Around the Ankle: A Narrative Review. *Diagnostics (Basel).* 2025;15(3):392. doi: 10.3390/diagnostics15030392. [DOI](#)
11. Hrubar Y, Hrubar I, Hrabak N et al. Change of the anterior talus-fibular ligament length of asymptomatic patients during inversion stress test. *Wiad Lek.* 2024;77(12):2435-24413. doi: 10.36740/WLek/195548. [DOI](#)
12. Aiyer A, Murali S, Kadakia AR. Advances in Diagnosis and Management of Lateral Ankle Instability: A Review of Current Literature. *J Am Acad Orthop Surg Glob Res Rev.* 2023;7(12):e23.00251. doi: 10.5435/jaaosglobal-d-23-00251. [DOI](#)
13. Beynon A, Le May S, Theroux J. Reliability and validity of physical examination tests for the assessment of ankle instability. *Chiropr Man Therap.* 2022;30(1):58. doi: 10.1186/s12998-022-00470-0. [DOI](#)
14. Hattori S, Onishi K, Chan CK et al. Optimal assessment for anterior talofibular ligament injury utilizing stress ultrasound entails internal rotation during plantarflexion. *J ISAKOS.* 2024;9(3):302-308. doi: 10.1016/j.jisako.2024.02.001. [DOI](#)
15. Schoonover C, Wright B. Variation in the anterior talofibular ligament and the impact of sex, height, weight, and age. *Clin Anat.* 2023;36(5):830-835. doi: 10.1002/ca.24056. [DOI](#)
16. Khawaji B, Soames R. The anterior talofibular ligament: A detailed morphological study. *Foot (Edinb).* 2015;25(3):141-147. doi: 10.1016/j.foot.2015.05.004. [DOI](#)
17. Dong Y, Qian Y, Liu L et al. Anatomical Study on the Reconstruction of the Anterior Talofibular Ligament. *J Foot Ankle Surg.* 2021;60(5):908-911. doi: 10.1053/j.jfas.2021.03.004. [DOI](#)
18. Szaro P, Ghali Gataa K, Solidakis N, Pękala P. Morphometric relationships between dimensions the anterior talofibular ligament and calcaneofibular ligament in routine magnetic resonance imaging. *J Exp Orthop.* 2021;8(1):90. doi: 10.1186/s40634-021-00406-2. [DOI](#)
19. Yokoe T, Tajima T, Kawagoe S et al. The Ratio of Stress to Nonstress Anterior Talofibular Ligament Length on Ultrasonography: Normative Values. *Orthop J Sports Med.* 2021;9(11):23259671211056305. doi: 10.1177/23259671211056305. [DOI](#)
20. Cho JH, Lee DH, Song HK et al. Value of stress ultrasound for the diagnosis of chronic ankle instability compared to manual anterior drawer test, stress radiography, magnetic resonance imaging, and arthroscopy. *Knee Surg Sports Traumatol Arthrosc.* 2016;24(4):1022-1028. doi: 10.1007/s00167-015-3828-9. [DOI](#)
21. Kamada K, Hoshino Y, Yamamoto T et al. Diagnostic strategies for chronic lateral ankle instability: a narrative review. *Ann Jt.* 2024;9:41. doi: 10.21037/aoj-24-31. [DOI](#)
22. Kikumoto T, Akatsuka K, Nakamura E et al. Quantitative evaluation method for clarifying ankle plantar flexion angles using anterior drawer and inversion stress tests: a cross-sectional study. *J Foot Ankle Res.* 2019;12:27. doi: 10.1186/s13047-019-0337-y. [DOI](#)

CONFLICT OF INTEREST

The Authors declare no conflict of interest

CORRESPONDING AUTHOR

Yurii Hrubar

Horbachevsky Ternopil National Medical University
1 Maidan Voli, 46001 Ternopil, Ukraine
e-mail: hrubar@ukr.net

ORCID AND CONTRIBUTIONSHIP

Yurii Hrubar: 0000-0002-4221-2250 [B](#) [C](#) [D](#)

Iryna Ya. Hrubar: 0000-0002-0809-1299 [A](#) [D](#) [E](#)

Markiiian Yu. Hrubar: 0000-0002-4696-0213 [B](#) [D](#) [E](#)

Yuliana Yu. Hrubar: 0000-0003-0951-9485 [A](#) [D](#) [F](#)

Nadiia M. Hrabyk: 0000-0002-8882-9782 **C** **D** **F**

Olha V. Hulka: 0000-0002-8364-5941 **A** **D** **F**

A – Work concept and design, **B** – Data collection and analysis, **C** – Responsibility for statistical analysis, **D** – Writing the article, **E** – Critical review, **F** – Final approval of the article

RECEIVED: 28.04.2025

ACCEPTED: 18.11.2025

